

## Case report

# DISPLACED FRACTURE OF THE FEMORAL SHAFT FROM KICKING THE GROUND DURING SOCCER - A CASE REPORT

Kei Miyamoto <sup>1</sup>✉, Masaji Morita <sup>1</sup>, Kazuaki Masuda <sup>2</sup>, Masato Maeda <sup>3</sup>, Hiroaki  
Terashima <sup>3</sup> and Katsuji Shimizu <sup>1</sup>

<sup>1</sup> Department of Orthopaedic Surgery, Gifu University School of Medicine, Yanagido 1-1, Gifu City, Gifu, Japan

<sup>2</sup> Department of Orthopaedic Surgery, Gihoku Kousei Hospital, Takatomi, Yamagata-City, Gifu, Japan

<sup>3</sup> Department of Orthopaedic Surgery, Takayama Red Cross Hospital, Tenman-Cho, Takayama-City, Gifu, Japan

Received: 03 October 2005 / Accepted: 08 November 2005 / Published (online): 01 December 2005

### ABSTRACT

We report a displaced femoral shaft fracture that occurred with no sign of contact-induced, stress, fatigue, or previous abnormal bone pathology in a 19-y-old man who kicked the ground instead of the ball when playing soccer. After examination to rule out abnormal bone pathology, intramedullary nailing was performed. Bone union was achieved and he could return to recreational soccer. Among soccer injuries, the occurrence of displaced femoral shaft fractures in the absence of stress, fatigue, or pathological fracture is rare. Awareness of such a rare cause of displaced femoral shaft fracture would help clinicians in the field of sports and soccer medicine.

**KEY WORDS:** Femoral shaft fracture, soccer, sports.

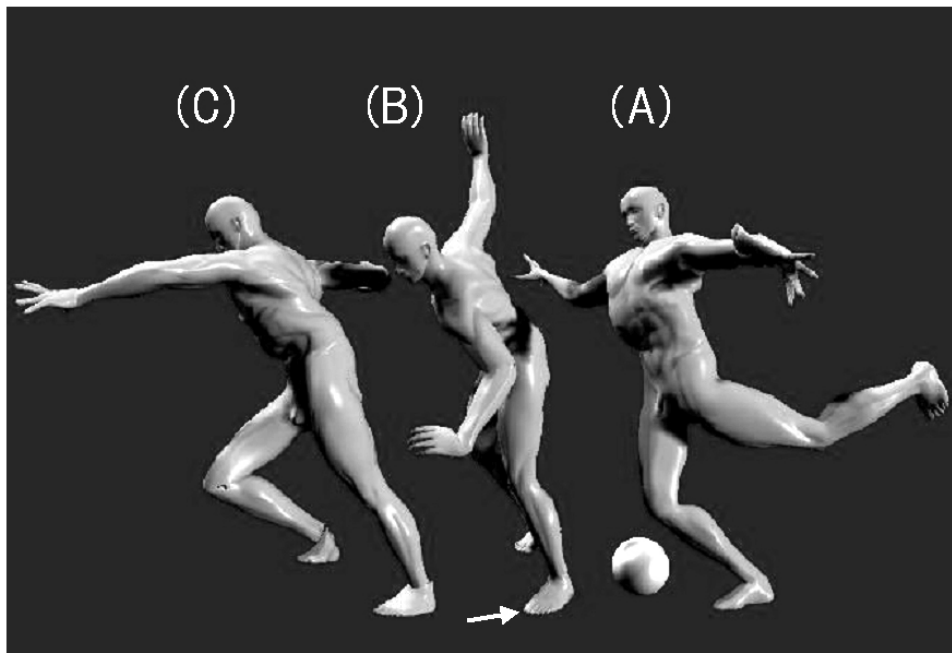
### INTRODUCTION

Soccer injuries to the lower extremities vary in nature (Hershman, et al., 1990; Hoff and Martin, 1986; Wong and Hong, 2005). However, the occurrence of displaced femoral shaft fractures in the absence of contact-induced (Goga and Gongal, 2003), stress (Boden and Speer, 1997; Ekstrand and Gillquist, 1983; Hoy, et al., 1992; Tamaki and Miyazaki, 1983; Yasuda, et al., 1992), fatigue, or pathological fracture is rare. We report a case of displaced femoral shaft fracture in a 19-y-old male who sustained this injury when he kicked the ground instead of the ball while playing soccer. We discuss the cause and mechanism of this rare injury, with reference to the literature.

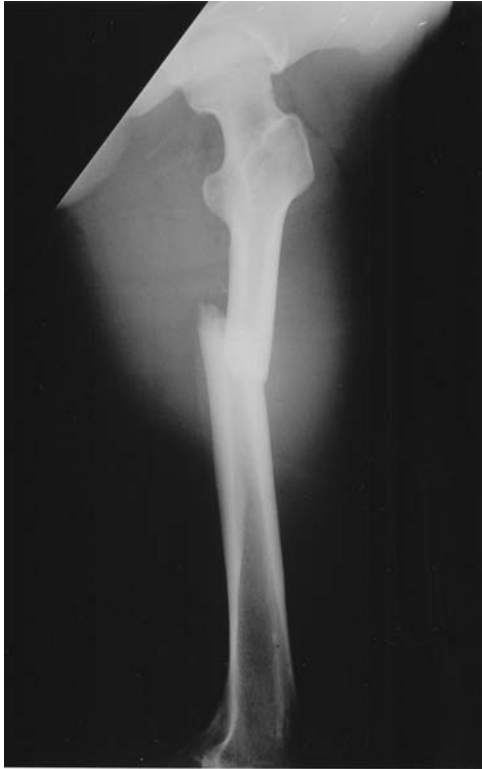### CASE REPORT

A 19-y-old male whose only sports activity was amateur soccer at a recreational level was playing his monthly match for a regional soccer union. He ran at full speed in spiked soccer shoes, trying to catch up with the ball, which was rolling ahead of him. When he caught up with the ball, he attempted to kick it with the side of his left foot, supporting his weight on the right foot (Figure 1-A). He kicked the ground instead of the ball (Figure 1-B), lost his balance and fell to the ground (Figure 1-C) with severe pain in the left thigh. The patient was unable to stand, and was admitted to our hospital.

When the patient was admitted, his left thigh showed distinct swelling and deformity. A plain



**Figure 1.** Illustration of the mechanism of fracture. (A) Player just about to kick the ball, with the right foot on the ground and the left leg slightly raised. (B) Player kicks the ground instead of the ball with the left foot (white arrow). (C) Player loses his balance and falls to the ground.



**Figure 2.** Plain radiograph on admission showed a displaced fracture of the left femur.

radiograph revealed a displaced fracture of the left femur (Figure 2). Neither periosteal reaction nor osteoblastic nor osteolytic change was apparent. On

hematological examination, a slight inflammatory reaction was observed, with a serum CPK level of  $422 \text{ IU}\cdot\text{L}^{-1}$ . Serum levels of alkaline phosphatase, calcitonin, and PTH were normal. Bone mineral density was normal at  $1035 \text{ g}\cdot\text{cm}^{-2}$  in the right femoral neck and  $1031 \text{ g}\cdot\text{cm}^{-2}$  in the lumbar spine. Fracture in a healthy, conditioned bone was the diagnosis. Closed intramedullary nailing was performed. Callus formation was observed 3 weeks postoperatively, suggesting a normal pattern of healing. Bone fusion was complete 6 months postoperatively and he could return to recreational soccer. Five years after surgery, the patient is uneventful.

## DISCUSSION

Soccer has gained popularity worldwide. It is characterized by intense exercise and contact during play. There have been many reports of soccer-related injuries in the literature, especially injuries to the lower extremities (Goga and Gongal, 2003; Hershman, et al., 1990; Hoff and Martin, 1986; Wong and Hong, 2005). Although the incidence of fractures during soccer games is relatively high (Goga and Gongal, 2003; Hershman, et al., 1990), displaced fractures of the femoral shaft are very rare: with 9 cases in the English literature (Goga and Gongal, 2003) and 2 in the Japanese literature (Kim,

et al., 1997; Tamaki and Miyazaki, 1983). Both of the Japanese cases were diagnosed as stress fractures with remarkable radiological findings and significant patient histories. Furthermore, femoral displaced fractures without any history of contact-induced are extremely rare. Indeed, stress fractures could well have been the initial differential diagnosis, because some authors have reported displaced fracture of the femur due to stress (Hoy, et al., 1992; Luchini, et al., 1983; Tamaki and Miyazaki, 1983). However, the present patient's low level of regular exercise, together with the absence of prodromal symptoms, hematological abnormalities and radiological abnormalities at the fracture site, led us to conclude that the kicking motion against the ground (Figure 1-A, B, C) itself caused an acute fracture in healthy bone.

From a mechanical viewpoint, the cause of our patient's femoral shaft fracture resembles that of femoral shaft fracture in skiers (Sterett and Krissoff, 1994). According to Sterett and Krissoff (1994), one of the causes of femoral shaft fractures during skiing is the transmission of an indirect flexion and rotation force to the femur. The force is produced by sudden entrapment of the skis when the skier hits wet or compacted snow at high speed. In our present patient, the spiked shoes presumably played a similar role as skis trapped in snow. Unexpectedly, the patient's foot, with its spiked shoe, was trapped on the hard ground. Both inertial force, which moved the upper body forward, and the force of contraction of the patient's muscles – in particular the iliopsoas and quadriceps muscles and the adductor muscles of the hip joint – would have produced an enormous flexion force on the femur.

Our patient's treatment outcome was excellent. The fracture had sufficient potential for bone regeneration and healed normally. As clinicians, we need to be aware that the force of kicking against the ground with full power is strong enough to produce a femoral shaft fracture.

## CONCLUSIONS

We reported a rare case of displaced femoral shaft fracture in a 19- y-old man, who sustained the injury when he kicked the ground instead of the ball during a soccer game.

## REFERENCES

Boden, B.P. and Speer, K.P. (1997) Femoral stress fractures. *Clinics in Sports Medicine* **16**, 307-317.  
 Ekstrand, J. and Gillquist, J. (1983) Soccer injuries and their mechanisms: a prospective study. *Medicine and Science in Sports and Exercise* **15**, 267-270.

Goga, I.E. and Gongal, P. (2003) Severe soccer injuries in amateurs. *British Journal of Sports Medicine* **37**, 498-501.  
 Hershman, E.B., Lombardo, J. and Bergfeld, J.A. (1990) Femoral shaft stress fractures in athletes. *Clinics in Sports Medicine* **9**, 111-119.  
 Hoff, G.L. and Martin, T.A. (1986) Outdoor and indoor soccer: injuries among youth players. *American Journal of Sports Medicine* **14**, 231-233.  
 Hoy, K., Lindblad, B.E., Terkelsen, C.J. and Helleland, H.E. (1992) European soccer injuries. A prospective epidemiologic and socioeconomic study. *American Journal of Sports Medicine* **20**, 318-322.  
 Kim, S.G., Sakuraba, K., Ikeda, H. and Yamauchi, Y. (1997) Stress fracture in the femoral shaft: A report of 4 cases. *Japanese Journal of Orthopaedic and Sports Medicine* **16**, 49-54.  
 Luchini, M.A., Sarokhan, A.J. and Micheli, L J. (1983) Acute displaced femoral-shaft fractures in long-distance runners. Two case reports. *Journal of Bone and Joint Surgery (Am)* **65**, 689-691.  
 Sterett, W.I. and Krissoff, W.B. (1994) Femur fractures in Alpine skiing: classification and mechanisms of injury in 85 cases. *Journal of Orthopaedic Trauma* **8**, 310-314.  
 Tamaki, S. and Miyazaki, K. (1983) Two cases of the displaced fatigue fracture of the femur. *Japanese Journal of Orthopaedic and Sports Medicine* **2**, 99-123.  
 Wong, P. and Hong, Y. (2005) Soccer injury in the lower extremities. *British Journal of Sports Medicine* **39**, 473-482.  
 Yasuda, T., Miyazaki, K., Tada, K., Matsuda, Y. and Murakami, H. (1992) Stress fracture of the right distal femur following bilateral fractures of the proximal fibulas. A case report. *American Journal of Sports Medicine* **20**, 771-774.

### KEY POINTS

- We report a very rare displaced femoral shaft fracture in a 19-y-old man who kicked the ground instead of the ball when playing soccer.
- Abnormal bone pathology was ruled out.
- Awareness of such a rare cause of displaced femoral shaft fracture would help clinicians in the field of sports and soccer medicine.

**AUTHORS BIOGRAPHY**

---

**Kei MIYAMOTO****Employment**

Ass. Prof. Department of Orthopaedic Surgery, Gifu University School of Medicine, Japan

**Degrees**

MD, PhD

**Research interests**

Spine surgery, Basic science of the spine, Biomechanics, Sports medicine.

**E-mail:** kei@bg8.so-net.ne.jp

---

**Masaji MORITA****Employment**

Graduate Student in the PhD course. Department of Orthopaedic Surgery, Gifu University School of Medicine, Japan

**Degree**

MD

**Research interests**

Cartilage metabolism, General orthopaedics

---

**Kazuaki MASUDA****Employment**

Director and Chief Orthopaedic Surgeon Department of Orthopaedic Surgery, Gihoku Kousei Hospital, Japan

**Degrees**

MD, PhD

**Research interests**

Joint reconstruction, arthroscopic surgery, spine surgery, traumatology, sports medicine.

---

**Masato MAEDA****Employment**

Director and Chief Orthopaedic Surgeon Department of Orthopaedic Surgery, Takayama Red Cross Hospital, Japan

**Degrees**

MD, PhD

**Research interests**

Joint reconstruction, spine surgery, traumatology, Sports medicine.

---

**Hiroaki TERASHIMA**

Attending orthopaedic surgeon, Department of Orthopaedic Surgery, Takayama Red Cross Hospital, Japan

**Degree**

MD

**Research interests**

Traumatology, sports medicine.

---

**Katsuji SHIMIZU**

Professor and Chairman, Department of Orthopaedic Surgery, Gifu University School of Medicine, Japan

**Degree**

MD, DMSc

**Research interests**

Spine surgery, cartilage metabolism.

---

**✉ Kei Miyamoto, MD, PhD**

Department of Orthopaedic Surgery, Gifu University Graduate School of Medicine, Yanagido 1-1, Gifu City, Gifu 501-1194, Japan