

## Research article

# AUGMENTATION VS NONAUGMENTATION TECHNIQUES FOR OPEN REPAIRS OF ACHILLES TENDON RUPTURES WITH EARLY FUNCTIONAL TREATMENT: A PROSPECTIVE RANDOMIZED STUDY

Gündüz Tezeren <sup>1</sup>✉ and İlhami Kuru <sup>2</sup>

<sup>1</sup>Cumhuriyet University School of Medicine. Department of Orthopaedics and Traumatology, Sivas, Turkey

<sup>2</sup>Kocatepe University School of Medicine. Department of Orthopaedics and Traumatology, Afyon, Turkey

Received: 10 July 2006 / Accepted: 13 September 2006 / Published (online): 15 December 2006

---

### ABSTRACT

A prospective randomized study was conducted in order to compare augmentation technique versus nonaugmentation technique, followed by early functional postoperative treatment, for operative repair of Achilles tendon ruptures. Twenty-four consecutive patients were assigned to two groups. Group I included 12 patients treated with Lindholm augmentation technique, whereas group II included 12 patients treated with modified Kessler end-to-end repair. Thereafter, these patients had postoperative management with a below-knee-cast for three weeks. The physiotherapy was initiated immediately after the cast was removed. Full weight bearing was allowed after five weeks postoperatively in the both groups. Two patients had reruptures in group II, whereas group I had prolonged operative time significantly. The patients with reruptures underwent reoperations and at the most final follow-up, it was observed that they could not resume to sporting activities. The other objective and subjective results were similar between two groups. Because of quite high rerupture rate in the group of patients treated with nonaugmentation technique, we favor functional postoperative treatment with early ankle movement in the patients treated with augmentation technique for the management of acute rupture of the Achilles tendon.

**KEY WORDS:** Achilles tendon, surgical procedure, early ambulation.

---

### INTRODUCTION

The Achilles tendon is the strongest and thickest tendon in the human body which takes its name from Achilles, the warrior of Homer's Iliad (Maffuli, 1999). Hippocrates stated "this tendon, if bruised or cut, causes the most acute fevers, induces choking, deranges the mind and at length brings death" (Carden et al., 1987). Since Ambroise Paré initially

described in 1575 and reported in the literature in 1633, Achilles tendon ruptures have received increasing attention (Cetti et al., 1993).

Rupture of the Achilles tendon is a serious injury and relatively common tendinous lesion (Bhandari et al., 2002; Cetti et al., 1993; Maffuli, 1999). It is estimated that the incidence of ruptures of the Achilles tendon was 18 per 100.000 (Leppilahti et al., 1996).

Frequently, acute ruptures of the Achilles tendon occur in men and in middle-aged people who are in third or fourth decade of life (Bradley et al., 1990; Maffuli, 1999; Kosanovic et al., 1994; Takao et al., 2003). Typically, they are weekend athletes who play a sport occasionally (Maffuli, 1999; Schram et al., 1988). Local corticosteroid injections are important, but tendinosis also is the one the major problem in the ruptured cases. Rheumatoid arthritis, diabetes mellitus and the other collagen diseases are the other causes of the ruptures.

The treatment of Achilles tendon ruptures remains a controversial issue. The main methods of the treatment include conservative and surgical techniques. Although there is a number of studies that favors conservative treatment (Lea et al., 1972; Nistor et al., 1981; Stein et al., 1976), surgical management seems preferable method (Bhandari et al., 2002; Cetti et al., 1994; Forste et al., 1974; Gillespie et al., 1969; Inglis et al., 1976; Jacobs et al., 1978; Möller et al., 2001; Schram et al., 1988). Advantages of surgical treatment are low rerupture rate and better functional results, and conservative treatment should be reserved for older patients (Lynch, 2004; Maffuli, 1999; Wills et al 1986; Wong et al 2002).

Many techniques are available for the surgical repair such as end-to-end suture, end-to-end suture with augmentation according to Teuffer (1974) or Bosworth et al. (1956) or Lindholm (1959), V-Y tendinous flaps (Abraham and Pankovich, 1975; Us et al., 1997), and augmentation with plantaris tendon (Lynn, 1966) as well as percutaneous repair techniques (Gorschewsky et al., 1999; Kosanovic et al., 1994; Ma and Griffith, 1977; Webb and Bannister, 1999).

There are many complications such as joint stiffness, muscle atrophy, tendocutaneous adhesions, and deep venous thrombosis due to prolonged immobilization after surgical repair of Achilles tendon ruptures (Mortensen et al., 1999, Wills et al., 1986). A number of studies have favored early functional treatment after operative treatment of the ruptured Achilles tendon (Kangas et al., 2003; Maffulli et al., 2003; Mortensen et al., 1999; Sorrenti, 2006; Suchak et al., 2006).

Early mobilization allows faster recovery and return to work (Maffulli et al., 2003). Sorrenti (2006) suggests that surgery combined with early mobilization reduces range of motion loss, increases blood loss, and reduces the degree of muscle atrophy. Early functional treatment protocols led to more excellent rated subjective responses (Suchak et al., 2006).

Disadvantages of early motion are that strength deficit and muscle atrophy are not

prevented (Maffulli et al., 2003). The main concern of early mobilization is rerupture (Sorrenti, 2006). We hypothesized that rerupture can be prevented with augmented surgical technique.

The purpose of this prospective study is to compare augmentation and nonaugmentation repair techniques, followed by early functional postoperative management, in the management of Achilles tendon ruptures.

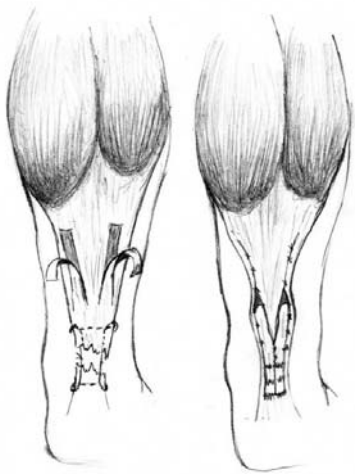
## METHODS

Between 1997 and 2000, a prospective randomized study was carried out. Twenty-four patients with acute closed total rupture of the Achilles tendon were included in this study. Study inclusion was limited to the patients who were younger than 60 years of age, in whom the rupture occurred less than 48 hours before admittance, who had no history of drug administration due to systemic disease, who had no history of previous Achilles tendon injury or who had no local corticosteroid injections around the Achilles tendon, and who were compliant and willing to surgical treatment, early postoperative functional treatment as well as follow-up process. The diagnosis based on a palpable gap in the tendon, a decrease of plantar flexion of the foot, a positive Thompson's test. All patients had opposite Achilles tendon examination as well.

The patients were simply randomized into two groups. Randomization was conducted according to order of admission of patients in emergency service, eg; first patient to group 1, second patient to group 2, third patient to group 1 and goes on. Group I included 12 patients treated with augmentation technique and group II included 12 patients treated with nonaugmentation technique.

All operations were performed under general anaesthesia. A tourniquet was always used. The patients were placed prone on the operating table. Posteromedial incision was used in all patients. Subcutaneous tissue freed carefully from the ruptured tendon. The paratenon was handled carefully and divided in same line. The frayed tendon ends were debrided. Care was taken the anterior mesentery as well as the lesser saphenous vein and the sural nerve. In the patients treated with augmentation (group I), operative technique included the use of gastrocnemius fascial flaps as described by Lindholm (1959) (Figure 1). Initially, the tendon was sutured with absorbable PDS (polydioxanone) 0-gauge sutures (Ethicon, Sommerville, New Jersey). Then, two gastrocnemius flaps approximately 1.0 cm wide and 7-8 cm long were prepared from the proximal tendon and gastrocnemius aponeurosis. These flaps were twisted

180° on itself so that smooth surface laid next to the subcutaneous tissue. The flaps were sutured distal stump of the tendon with 3-0 Vicryl sutures (Ethicon). The donor site of flaps was closed with same Vicryl sutures. In the patients treated with nonaugmentation (group II), a modified Kessler end-to-end suture technique with a PDS 0-gauge suture and smaller apposition sutures with Vicryl were used for the repair of the ruptured Achilles tendon. Following the paratenon (protection of the paratenon is important owing to source of stem cell), the fascia and the subcutaneous tissue were sutured with Vicryl, the skin was closed with nylon sutures (Ethicon).



**Figure 1.** Operative technique described by Lindholm (1959).

All of the patients casted in gravity equinus with below-knee plaster cast. The cast was kept in place for three weeks. It then was removed, and rigorous physical therapy was initiated. Physical therapy included active and passive ankle movements in all directions. On nighttimes, a splint was applied in which gradually dorsiflexion was performed. Five weeks postoperatively, full weight bearing was allowed. Resisted ankle movements were added at 6 weeks. We advised the patients to

use 1 cm heel lift in the shoes for a month. The permission of resuming to the sporting activities varied according to individuals' condition. Rehabilitation program was shown in Table 1.

Follow-up routine examinations were carried out at 4, 8 and 12 weeks and 4, 6, 12, 18 and 24 months. After the second year, the patients were followed twice a year. Clinical outcome was assessed with data at 2 years postoperatively in an attempt to provide the uniformity. The examinations initiated with an interview regarding the patients' comments that include pain, swelling, discomfort in wearing shoes, stiffness, sick leave time, and resumption of the sports. The patients were asked their opinion as excellent, satisfied, or not satisfied.

Thickening of the healed tendon, calf circumference, range of movement at the ankle, dorsal shift, plantar shift, and ability on tiptoe while standing and walking were assessed and recorded. Dorsal shift means hyperextension in ankle motion with respect to uninjured extremities which indicates an elongated Achilles tendon. Sensibility of the sural nerve was tested by asking the patients whether there was a normal feeling on lateral border of the foot. Visible adhesions of the scar to the tendon was observed according to the classification adopted by Mortensen et al. (1999), grade 0 is assigned when there is no adherence; grade 1 indicates minor adherence with movement of the ankle; grade 2 indicates visible adherence even without movement of the ankle.

Cybox II dynamometer (Cybex, Inc., Ronkonkoma, New York, USA) was used for concentric plantar flexion isokinetic strength testing on both lower extremities for comparison. Each limb was tested with a rapid range of motion at each of two different machine settings (30 and 120 deg·sec<sup>-1</sup>).

The unpaired *t* test was used to compare age, operation time, time between injury and operation, operation time, sick leave time, time of resuming to sporting activities, hospitalization time, thickness of the Achilles tendon, and loss of calf circumference.

**Table 1.** Rehabilitation program.

Time	Program
0-3 weeks	Cast with 10-15 degrees dorsiflexion
3-5 weeks	Cast removed. No walking was allowed. Active and passive ankle motion without resistance daily by a physiotherapist. Residual equinus is overcome with passive dorsiflexion. Nighttime splinting with gradually dorsiflexion. Massage of skin.
5-6 weeks	Walking exercises. Full immobilization was encouraged without brace.
6 <sup>th</sup> postoperative week	Resisted active and passive ankle motion. Swimming, cycling.
12 <sup>th</sup> postoperative week	Beginning with training of sports according to individual condition.

To compare gender, subjective opinion of the patients, rerupture rate, dorsal shift, and discomfort in footwear rate Fisher's exact test was performed and Chi-Square test was used to compare adhesions of the scar to the tendon. MedCalc statistical software (MedCalc Software, Mariakerke, Belgium) was used for statistical analyses. A *p* value of < 0.05 was considered significant.

## RESULTS

The study included 18 male and 6 female patients. The mean age of the patients was 35.5 years (range 22-54 years). The rupture was left-sided in 14 and on the right in ten. In 20 patients, the rupture occurred during sports (Table 2). Mean follow-up was 32.6 months (range 24-43 months). All patients were operated as immediately as admittance procedures and medical consultations were completed.

**Table 2.** Causes of Achilles tendon ruptures.

	Group I (n = 12)	Group II (n = 12)
Gender (Male/Female)	8/4	10/2
Injured side (Left/Right)	9/3	5/7
Soccer (n = 7)	4	3
Jogging (n = 4)	2	2
Basketball (n = 3)	1	2
Tennis (n = 2)	2	0
Squash (n = 2)	1	1
Aerobics (n = 1)	0	1
Not during sports (n = 5)	2	3

In the patients treated with augmentation, the mean age was  $36.1 \pm 10.9$  years (range 22-45 years) and in the patients treated with nonaugmentation, the mean age was  $34.8 \pm 5.6$  (range 24-41 years). There were no significant differences between the two groups according to age and gender. The mean operation time was  $66.6 \pm 7.4$  minutes (range 60-75 minutes) in the patients treated with augmentation

and  $52.5 \pm 6.9$  minutes (range 45-60 minutes) in the patients treated with nonaugmentation which was significantly lesser ( $p = 0.0001$ ).

The mean time between the injury and the operation was  $7.4 \pm 4.1$  hours (range 3-16 hours), the mean hospitalization time was  $3.8 \pm 1.1$  days (range 2-6 days) in the patients treated with augmentation and  $10.0 \pm 5.5$  hours (range 3-24 hours),  $3.6 \pm 1.2$  days (range 2-6 days) respectively in the patients treated with nonaugmentation. The mean follow-up time was  $33.4 \pm 5.5$  months (range 24-41 months) in the patients treated with augmentation and  $31.8 \pm 6.4$  months (range 24-43 months) in the patients treated with nonaugmentation. There were no significant differences between the two groups according to time between injury and operation, and hospitalization time.

The patients stated their subjective opinion regarding the final outcome which as follows: excellent in 7 patients, satisfied in 4 patients, and not satisfied in 1 patient with augmentation and excellent in 5 patients, satisfied in 4 patients, not satisfied in 3 patients with nonaugmentation. Therefore, 11 patients satisfied in group I, whereas 9 patients satisfied in group II. The mean sick leave time and the time before return to sporting activities were  $36.5 \pm 18.5$  days (range 7-60 days) and  $5.1 \pm 1.1$  months (range 3-6 months) in patients with augmentation respectively, and  $48.3 \pm 32.4$  days (range 7-120 days) and  $5.4 \pm 1.4$  months (range 3-8 months) in patients with nonaugmentation respectively. There were no significant differences between the two groups according to subjective opinion of the patients, sick leave time, and time of resuming to sporting activities.

The thickness of the Achilles tendon was similar between the two groups. The mean loss of calf circumference between the injured and uninjured extremities was also similar between the two groups which were  $1.1 \pm 1.0$  cm (range 0-3 cm) and  $1.7 \pm 1.5$  cm (range 0-5 cm) in the group I and II

**Table 3.** Concentric plantar-flexion torques (Nm) of the patients. Data are means ( $\pm$ SD) [range].

Side	Angular velocity (degree·sec <sup>-1</sup> )	Group I (n=12)	Group II (n=12)
Injured	30	78.8 (22.0) [49-118]	61.3 (30.8) [21-115]
Noninjured	30	89.6 (23.7) [49-120]	81.9 (26.1) [45-118]
Injured	120	41.9 (13.0) [18-67]	30.2 (15.7) [10-52]
Noninjured	120	51.6 (14.2) [27-78]	45.3 (14.8) [20-65]

respectively ( $p = 0.30$ ). At the most recent follow-up, there was no decreased range of motion at ankle in the patients with augmentation, however, two patients who had a rerupture in the group with nonaugmentation had decreased range of motion by  $15^\circ$  and  $10^\circ$ .

Eight patients were rated as grade 0, three were grade 1, and one was grade 2 in group I, whereas seven patients were rated as grade 0, three were grade 1, two were grade 2 in group II for the adhesions of the scar to the tendon according to classification adopted by Mortensen et al. (1999). The difference was not significant.

No patients had a rerupture in the augmentation group, whereas two patients had a rerupture in the nonaugmentation group. The reruptures occurred 15<sup>th</sup>, and 24<sup>th</sup> weeks postoperatively. One of them was due to a fall. Other one occurred while walking. They underwent open repair with Lindholm technique immediately when rerupture occurred. Those patients delayed to return to final functional activities by 16 and 19 weeks. Moreover, those patients could not return to the sporting activities. No patients used the cane except two rerupture cases; however there is no statistically difference between two groups.

None of the patients had a dorsal shift in the augmentation group, whereas 2 patients had a dorsal shift ( $2^\circ$  and  $3^\circ$ ) in the nonaugmentation group. No patients had a plantar shift in the both groups. No patients had sural nerve palsy. No patients had a footwear problem in group I, whereas 2 patients who had reruptures had mild footwear problems in group II. There were no significant differences between the two groups according to rerupture, dorsal shift, and discomfort in footwear rate. No patients had stiffness in group I, whereas two patients had stiffness in group II. The patients who had stiffness were those who had a secondary operation due to the rerupture. There was one deep infection treated by debridement and antibiotics in group I in whom grade 2 adhesion to the skin was obtained.

All the patients underwent Cybex testing. Results of the measurements are shown in Table 3. Twenty-three patients had less plantar flexion strength on the injured extremity than on the uninjured extremity. One patient treated with augmentation had greater plantar flexion strength on the injured extremity. Two patients with reruptures showed obviously diminished plantar flexion strength compared to the uninjured extremity.

## DISCUSSION

Treatment of Achilles tendon ruptures remains controversial. Many treatment methods have been

published in literature. Some of them favored conservative treatment that included cast management without surgical intervention (Lea et al., 1972; Nistor et al., 1981; Stein et al., 1976), while others advocated surgical treatment (Bhandari et al., 2002; Cetti et al., 1994; Forste et al., 1974; Gillespie et al., 1969; Inglis et al., 1976; Jacobs et al., 1978; Möller et al 2001; Schram et al., 1988). Wong et al. (2002) demonstrated in their meta-analysis that open repair and early mobilization is probably method of choice.

It is known that immobilization of the tendon tends to diminished healing so that decreased blood supply (Cetti et al., 1994). This opinion supports the early mobilization after the repair of Achilles tendon ruptures. On the contrary, it is also known that early functional treatment can cause the elongation and rerupture of repaired Achilles tendon (Cetti et al., 1994). The point may be laid on how strong the tendon has been repaired. We believe that a repair of the ruptured Achilles tendon should be strong enough in attempt to begin early functional treatment. In the present study, augmentation technique that had been described by Lindholm provided safe and strong construction in the repair of acute Achilles tendon ruptures.

Rigid immobilization for four to nine weeks has been accepted treatment after the repair of the ruptured Achilles tendon. Early motion after surgical repair in an effort to reduce the risk of complications due to prolonged immobilization has been taken place in this field since 1980's (Kangas et al., 2003; Mortensen et al., 1999). However, there are some risks of early motion that are the elongation or breakdown of repair. The present study was constituted under a hypothesis that these risks would be eliminated with an augmented repair of the tendon. As a result, none vs two reruptures were found in the patients treated with augmentation and nonaugmentation techniques respectively.

The rates of adhesions to the skin were ranged from 10.7% to 44% in different studies (Cetti et al., 1993; Nistor, 1981). Lim et al. (2001) declared 6% in the open group compared to none in the percutaneous group; therefore, they concluded that the adhesions were rarely seen after percutaneous repair. In the present study, major adhesions were encountered in one versus two patients in group I and II respectively.

In the experimental study of Gardes et al (Gerdes et al., 1992) demonstrated that the augmentation technique with a central gastrocnemius aponeurosis flap had greater strength than a standard Kessler repair. They studied on 18 paired fresh anatomic Achilles tendons and resulted that the augmentation technique was 217 Newton,

while the nonaugmentation technique was 154 Newton. In a series of 318 patients, Winter et al (1998) concluded that facial reinforced repair offered a lower rate of rerupture (0.4%) compared with end-to-end suturing.

Buchgraber and Pässler (1997) favored functional postoperative treatment, even in the patients treated with percutaneous repair. Takao et al. (2003) suggested that with Lindholm procedure, it was possible to begin postoperative rehabilitation at an early stage after the repair of neglected rupture of the Achilles tendon.

It has been mentioned that the consequence of rerupture, which is a serious problem, is well known (Cetti, 1993). The rate of rerupture in nonaugmentation technique is reported as 5.1% by Nyssonen et al. (2003), 4.5% by Nistor (1981), 5.4% by Cetti et al. (1993), 6% by Lim et al. (2001), 1.7% by Möller et al. (2001), 6% by Kangas et al. (2003). We consider that it can not be explained with the statistical numbers in some instances. Our two rerupture cases in Group II could not resume to sporting activities. These reruptures may depend on early active and passive exercise program which is used in both groups.

Although there is no major statistical difference between the two groups, we do not recommend end-to-end suturing technique with early mobilization. However, augmentation technique seems reliable and safe with early functional treatment. On the contrary, Nyssonen et al. (2003) suggested that end-to-end suture had less complication rate. However, they found 2 versus 1 reruptures in the end-to end-suture group comparing augmentation group.

The weaknesses of this study include having small series; others are that sick leave time and resumption of sporting activities which were assessed by treating orthopaedic surgeon. These should have been employed by blinded person.

## CONCLUSION

In conclusion, this prospective study demonstrates that both group of patients treated with augmentation and nonaugmentation followed by early functional treatment had similar outcome taking into consideration of the subjective and objective results statistically. However, the group of patients treated with augmentation had prolonged operative time, whereas two patients had reruptures in the group of patients treated with nonaugmentation compared with no patients had reruptures in the group of patients treated with augmentation. We favor functional postoperative treatment with early ankle movement in the patients treated with augmentation

for the management of acute rupture of the Achilles tendon. However, we believe that further clinical studies which include large series should be performed in order to assess the outcome of early functional postoperative treatment.

## ACKNOWLEDGEMENT

The present study was performed in Bayindir Hospital, Ankara, Turkey

## REFERENCES

- Abraham, E. and Pankovich, A.M. (1975) Neglected ruptures of Achilles tendon. *Journal of Bone and Joint Surgery (American)* **57**, 253-255.
- Bhandari, M., Guyatt, G.H., Siddique, F., Morrow, F., Busse, J., Leighton, L.K., Sprague, S. and Schemitsch E.H. (2002) Treatment of acute Achilles tendon ruptures a systematic overview and metaanalysis. *Clinical Orthopaedics Related Research* **400**, 190-200.
- Bradley, J.P. and Tibone, J.E. (1990) Percutaneous and open surgical repairs of Achilles tendon ruptures. *American Journal of Sports Medicine* **18**, 188-195.
- Bosworth, D.M. (1956) Repair of defects in the tendo Achillis. *Journal of Bone and Joint Surgery (American)* **38**, 111-114.
- Buchgraber, A. and Pässler, H.H. (1997) Percutaneous repair of Achilles tendon rupture. Immobilization versus functional postoperative treatment. *Clinical Orthopaedics Related Research* **341**, 113-122.
- Carden, D.G., Noble, J., Chalmers, J., Lunn, P. and Ellis, J. (1987) Rupture of the calcaneal tendon. The early and late management. *Journal of Bone and Joint Surgery (British)* **69**, 416-420.
- Cetti, R., Christensen, S.E., Ejsted, R., Jensen, N.M. and Jorgensen, U. (1993) Operative versus nonoperative treatment of Achilles tendon rupture. A prospective randomized study and review of the literature. *American Journal of Sports Medicine* **21**, 791-799.
- Cetti, R., Henriksen, L.O. and Jacobsen, K.S. (1994) A new treatment of ruptured Achilles tendons. A prospective randomized study. *Clinical Orthopaedics Related Research* **308**, 155-165.
- Forste, R.L., Ritter, M.A. and Young, R. (1974) Rerupture of a conservatively treated Achilles tendon rupture. *Journal of Bone and Joint Surgery (American)* **56**, 174-175.
- Gerdes, M.H., Brown, T.D., Bell, A.L., Baker, J.A., Levson, M. and Layer, S. (1992) A flap augmentation technique for Achilles tendon repair. Postoperative strength and functional outcome. *Clinical Orthopaedics Related Research* **280**, 241-246.
- Gillespie, H.S. and George, E.A. (1969) Results of surgical repair of spontaneous rupture of the Achilles tendon. *Journal of Trauma* **9**, 247-249.

- Gorschewsky, O., Vogel, U., Schweizer, A. and van Laar, P. (1999) Percutaneous tenodesis of the Achilles tendon. A new surgical method for the treatment of acute Achilles tendon rupture through percutaneous tenodesis. *Injury* **30**, 315-321.
- Inglis, A.E., Scott, W.N., Sculco, T.P. and Patterson, A.H. (1976) Ruptures of the tendo Achillis. *Journal of Bone and Joint Surgery (American)* **58**, 990-993.
- Jacobs, D., Martens, M., Van Audekercke, R., Mulier, J.C., and Mulier, F. (1978) Comparison of conservative and operative treatment of Achilles tendon rupture. *American Journal of Sports Medicine* **6**, 107-111.
- Kangas, J., Pajala, A., Siira, P., Hamalainen, M. and Leppilahti, J. (2003) Early functional treatment versus early immobilization in tension of the musculotendinous unit after Achilles rupture repair: A prospective, randomized, clinical study. *Journal of Trauma* **54**, 1171-1180.
- Kosanovic, M., Cretnik, A. and Batista, M. (1994) Subcutaneous suturing of the ruptured Achilles tendon under local anaesthesia. *Archives of Orthopaedic and Trauma Surgery* **113**, 177-179.
- Lea, R.B. and Smith, L. (1972) Non-surgical treatment of tendo Achillis rupture. *Journal of Bone and Joint Surgery (American)* **54**, 1398-1407
- Leppilahti, J., Puranen, J. and Orave, S. (1996) Incidence of Achilles tendon rupture. *Acta Orthopaedica Scandinavica* **67**, 277-279.
- Lim, J., Dalal, R. and Waseem, M. (2001) Percutaneous vs open repair of the ruptured Achilles tendon. A prospective randomized controlled study. *Foot and Ankle International* **22**, 559-568.
- Lindholm, A. (1959) A new method of operation in subcutaneous rupture of the Achilles tendon. *Acta Chirurgica Scandinavica* **117**, 261-270.
- Lo, I.K., Kirkley, A., Nonweiler, B. and Kumbhare, D.A. (1997) Operative versus nonoperative treatment of acute Achilles tendon ruptures. A quantitative review. *Clinical Journal of Sport Medicine* **7**, 207-211.
- Lynch, R.M. (2004) Achilles tendon rupture: surgical versus non-surgical treatment. *Accident Emergency Nursing* **12**, 149-158.
- Lynn, T.A. (1966) Repair of the torn Achilles tendon using the plantaris tendon as a reinforcing membrane. *Journal of Bone and Joint Surgery (American)* **48**, 268-272.
- Ma, G.W.C. and Griffith, T.G. (1977) Percutaneous repair of acute closed ruptured Achilles tendon. A new technique. *Clinical Orthopaedics Related Research* **128**, 247-255.
- Maffulli, N. (1999) Current concepts review: Rupture of the Achilles tendon. *Journal of Bone and Joint Surgery (American)* **81**, 1019-1036.
- Maffulli, N., Tallon, C., Wong, J., Lim, K.P. and Bleakney, R. (2003) Early weightbearing and ankle mobilization after open repair of acute midsubstance tears of the Achilles tendon. *American Journal of Sports Medicine* **31**, 692-700.
- Mortensen, N.H.M., Skov, O. and Jensen, P.E. (1999) Early motion of the ankle after operative treatment of a rupture of the Achilles tendon: A prospective randomized clinical and radiographic study. *Journal of Bone and Joint Surgery (American)* **81**, 983-990.
- Möller, M., Movin, T., Granhed, H., Lind, K., Faxen, E. and Karlsson, J. (2001) Acute rupture of tendo Achillis. A prospective randomized study of comparison between surgical and non-surgical treatment. *Journal of Bone and Joint Surgery (British)* **83**, 843-848.
- Nistor, L. (1981) Surgical and non-surgical treatment of Achilles tendon rupture. A prospective randomized study. *Journal of Bone and Joint Surgery (American)* **63**, 394-399.
- Nyyssonen, T., Saarikoski, H., Kaukonen, J.P., Luthje, P., and Hakovirta, H. (2003) Simple end-to-end suture versus augmented repair in acute Achilles tendon ruptures. A retrospective comparison in 98 patients. *Acta Orthopaedica Scandinavica* **74**, 206-208.
- Schram, A.J., Landry, J.R. and Pupp, G.R. (1988) Complete rupture of the Achilles tendon: A new modification for primary surgical repair. *Journal of Foot Surgery* **27**, 453-457.
- Stein, S.R. and Luekens, C.A. (1976) Closed treatment of Achilles tendon ruptures. *Orthopedic Clinics of North America* **7**, 241-246.
- Sorrenti, S.J. (2006) Achilles tendon rupture: effect of early mobilization in rehabilitation after surgical repair. *Foot and Ankle International* **27**, 407-410.
- Suchak, A.A., Spooner, C., Reid, D.C. and Jomha, N.M. (2006) Postoperative rehabilitation protocols for Achilles tendon ruptures. *Clinical Orthopaedics Related Research* **445**, 216-221.
- Takao, M., Ochi, M., Naito, K., Uchio, Y., Matsusaki, M. and Oae, K. (2003) Repair of neglected Achilles tendon rupture using gastrocnemius fascial flaps. *Archives of Orthopaedic and Trauma Surgery* **123**, 471-474.
- Teuffer, A.P. (1974) Traumatic rupture of the Achilles tendon: reconstruction by transplant and graft using the lateral peroneus brevis. *Orthopedic Clinics of North America* **5**, 89-95.
- Us, A.K., Bilgin, S.S., Aydin, T. and Mergen, E. (1997) Repair of neglected Achilles tendon ruptures: procedures and functional results. *Archives of Orthopaedic and Trauma Surgery* **116**, 408-411.
- Webb, J.M. and Bannister, G.C. (1999) Percutaneous repair of the ruptured tendo Achillis. *Journal of Bone and Joint Surgery (British)* **81**, 877-880.
- Wills, C.A., Washburn, S., Caiozzo, V. and Prietto, C.A. (1986) Achilles tendon rupture. A review of the literature comparing surgical versus nonsurgical treatment. *Clinical Orthopaedics Related Research* **207**, 156-163.
- Winter, E., Weise, K., Weller, S. and Ambacher, T. (1998) Surgical repair of Achilles tendon rupture. *Archives of Orthopaedic and Trauma Surgery* **117**, 364-367.
- Wong, J., Barrass, V. and Maffulli, N. (2002) Quantitative review of operative and nonoperative

management of Achilles tendon ruptures. *American Journal of Sports Medicine* **30**, 565-575.

### KEY POINTS

- A prospective randomized study was conducted in order to compare augmentation technique versus nonaugmentation technique, followed by early functional postoperative treatment, for operative repair of Achilles tendon ruptures.
- Group I included 12 patients treated with Lindholm augmentation technique, whereas group II included 12 patients treated with modified Kessler end-to-end repair.
- Functional postoperative treatment with early ankle movement in the patients treated with augmentation for the management of acute rupture of the Achilles tendon is recommended.

### AUTHORS BIOGRAPHY

---

#### **Gündüz TEZEREN**

##### **Employment**

Associate Professor, Department of Orthopaedics and Traumatology. Cumhuriyet University School of Medicine, Sivas, Turkey

##### **Degree**

MD

##### **Research interest**

Sports traumatology, spinal surgery, pediatric orthopaedics.

**E-mail:** gtezeren@yahoo.com

---

#### **Ilhami KURU**

##### **Employment**

Associate Professor. Department of Orthopaedics and Traumatology. Kocatepe University School of Medicine, Afyon, Turkey

##### **Degree**

MD

##### **Research interest**

Sports traumatology, upper extremity surgery.

**E-mail:** ikuru@isnet.net.tr

---

#### ✉ **Dr. Gündüz Tezeren**

Cumhuriyet University, P.K. 769, 58140 Sivas, Turkey.