

Case report

Stress fracture of the ulna in a break-dancer

Yu-Hsu Chen, Chun-Lin Kuo, Leou-Chyr Lin, Shyu-Jye Wang and Chian-Her Lee ✉

Department of Orthopaedics, Tri-Service General Hospital, Taipei City, Taiwan (R.O.C)

Abstract

Break dancing is a popular activity in teenagers and is associated with severe trauma to bones and tissues. We report the first known case of a break dancer with an ulnar stress fracture. Such injuries occur in a variety of sports due to substantial stress on the ulna and repetitive excessive rotation of the forearm. In this study we describe a patient who experienced an ulnar stress fracture during break dancing training. The diagnosis was established by history and physical examination. Initial radiographic findings were negative. However, radiographs taken 3 months after initial presentation revealed callus formation over the ulnar shaft. This suggested that readjustment is required in break dancing training protocols. It is important to increase awareness of this injury among physicians to expedite the diagnosis and to prevent the possibility of conversion to an overt fracture in the future.

Key words: Sports injuries, ulna fractures, stress fractures, magnetic resonance imaging.

Introduction

Break dancing has been a potentially dangerous form of recreation since its appearance in popular American culture in the late 1980s. Many fundamental break dancing moves require support of body weight by the hands and arms as the feet and legs move the body around an axis. Severe bone and tissue trauma have been described in many cases in the medical literature (Goscienski and Luevanos, 1984). To our knowledge, this is the first identified case

of an ulnar shaft stress fracture in a break dancer.

Case history

A 16-year-old male patient reported right forearm pain of 3 weeks duration during preparation for an upcoming break dancing performance. The pain was most pronounced during right forearm rotation and right wrist extension. The patient taped the arm for 4 to 5 days for increased support and did not take pain medication. The patient increased his daily practice time to a daily total of 6 hours, particularly for the hand glide position. This position included a spin on the right hand supporting the entire body weight with torsional stress present on the right forearm (Figure 1). His pain became so severe during the performance that he was unable to support his body weight on the right arm. A visible swelling subsequently developed in the forearm.

Physical exam findings on clinical presentation included mild tenderness on right wrist palpation and significant tenderness over the middle third of the ulnar shaft. The patient reported increased pain upon resisted dorsal flexion of the wrist and significantly increased pain with a fulcrum-type ulnar valgus stress. Initial radiographic findings were insignificant (Figure 2A).

The clinical history and presentation were strongly suggestive of a stress fracture of the middle third of the ulnar shaft. The patient was advised to restrict both weight bearing and rotational physical activities of the right forearm. Follow-up radiographs after 3 months



Figure 1. “HAND GLIDE” is a type of spin usually performed while balanced in a one-handed float position.

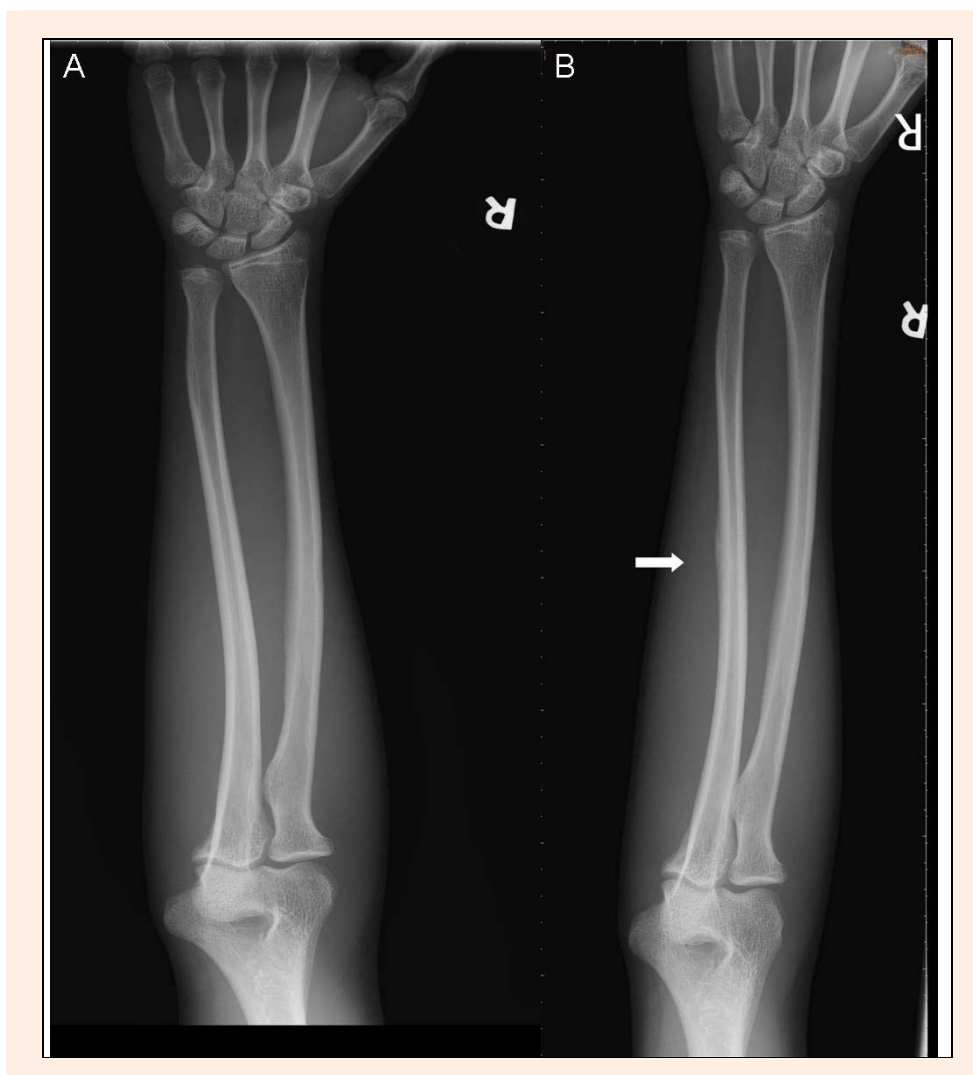


Figure 2. Radiographs of the ulnar shaft at presentation (A) and at three months (B). Note the solid callus formation (arrow) over the middle-one third of the ulna, confirming stress fracture of the shaft.

revealed solid callus formation on the medial aspect of the middle third of the ulnar shaft (Figure 2B). The right arm was able to bear full body weight in the hand glide position at 6 months after treatment (Figure 1).

Discussion

The spinning movements which occur during break dancing acrobatics are often performed with the body weight supported by one or more hands and arms. These positions may be maintained for several seconds, and several types of trauma are associated with break dancing, including spinal fractures and subluxations (Byun et al., 1986; Dorey and Mayne, 1986; McBride et al., 1985; Ramirez et al., 1984), back swelling and spinal bursitis (Moses and Shannon, 1985), subdural hematomas (Lee and Clough, 1990; McNeil et al., 1987), ocular trauma (Joondeph et al., 1986), genitourethral trauma (Gearhart and Lowe, 1986; Wheeler and Appell, 1984), friction-associated skin problems (Sharma et al., 1986), pneumothorax (Balfour-Lynn, 2002), infrapatellar bursa (Broome and Heppinstall, 1985), chronic avulsion of the anterior superior iliac spine (Winslet et al., 1986), and various fractures in the extremities (Ihmeidan et al. 1987).

The mechanisms involving ulnar stress fractures remain unclear. Postulated causes of upper extremity stress fractures include repetitive muscle tension, torsion forces, and compression forces. Ulnar stress fractures have been reported in athletes who exert substantial physical stresses on the ulna by repetitive excessive pronation during sports. These have been seen in tennis players who use double-handed backhand strokes (Rettig, 1983), softball pitchers (Tanabe et al., 1991), table tennis players (Petschnig et al., 1997), weight lifters or bodybuilders who lift excessive weights (Hamilton, 1984), or bowlers with repeated flexor profundus muscle contraction (Escher, 1997).

The clockwise spin performed in the hand glide position while balanced in a right-handed float position resulted in at least 3 causes of stress. First, wrist hyperextension resulted in contraction forces at the middle third of the ulnar shaft at the insertion sites of the extensor carpi ulnaris and extensor pollicis longus. Next, one-handed standing positions results in compression forces through the rotation center axis of the forearm from the radial head to the distal ulna (Nakamura et al., 1999) with full body weight. Lastly, clockwise right-handed spins resulted in torsion forces over the middle third of the

ulnar shaft when radial position around the ulna shifted from supination to pronation (Nakamura et al., 2000). A previous study by Tanabe et al. found that the ulnar rotation was restricted with the small rotation range of the brachioradial and distal radioulnar joints and allowed a strong radial revolving force during forceful pronation and acted on the ulna. Morphologic studies indicated that the cross-sectional area of the middle third of the ulna was triangular-shaped, smaller, and had thinner cortices than other parts of the bone. These findings implied that stress fractures readily developed in the middle third of the ulna when the ulnar shaft sustained excessive torsion forces (Tanabe et al., 1991).

The upper extremities are frequently used to support body in both gymnastics and in break dancing. Events such as the pommel horse, floor exercise, and balance beam include many elements that result in recurrent loading of the upper limbs with relatively large static and dynamic forces. To our knowledge, this is the first stress fracture of the ulnar shaft associated with break dancing in the medical literature. Unlike gymnastics, break dancing is usually carried out without supervision. Although break dancing is very appealing to children and teenagers it frequently lacks suitable venues and training (Johnson and Jones, 1986). Break dancing moves are associated with sudden increases in loads and frequencies of training, and is strongly associated in ulnar stress fractures. Other examples include large weight increases during training in weight lifters and increasing training length times in tennis and tennis and table tennis players (Hamilton, 1984; Rettig, 1983). The patient added 2 to 4 hours of extra training per day for 2 weeks prior to break dancing performances, and this may have contributed to the injury.

The biomechanical loading, poor training courses, and overtime activity of break dancing combined with anatomic weakness, and this collectively resulted in a stress fracture of the middle third of the ulna in this patient. Plain radiographs are diagnostically useful when positive, but generally have low sensitivity. Radionuclide bone scanning is highly sensitive, but lacks specificity and the ability to directly visualize fracture lines. Magnetic resonance imaging (MRI) provides highly sensitive and specific evaluation for bone marrow edema and periosteal reaction as well as for the detection of subtle fracture lines. However, MRI is expensive and does not contribute to further clinical management. A thorough clinical history, complete physical examination, and plain radiography comprised the diagnostic work-up in this patient. Bone scans and MRI studies are useful when plain radiographs are equivocal and a definitive diagnosis is required rapidly. Our data suggest that some readjustment is required in the training protocol for break dancers to minimize and prevent the likelihood of ulnar stress fractures.

Conclusion

Break dancing is a widely practiced activity with unique physical demands and associated medical problems. A clinical history of break dancing may change or enhance a differential diagnosis, even in non-orthopedic settings.

The patient's clinical history and physical examination were initially used to diagnose a stress fracture despite a normal radiographic study, and this early diagnosis may have prevented conversion to an overt fracture.

References

- Balfour-Lynn, I.M. (2002) Break dancer's lung. *Archives of Disease in Childhood* **86**, 224.
- Broome, H.E. and Heppenstall, R.B. (1985) Break dancers' bursitis. *The Journal of the American Medical Association* **253**, 777.
- Byun, H.S., Cantos, E.L. and Patel, P.P. (1986) Severe cervical injury due to break dancing. A case report. *Orthopedics* **9**, 550-551.
- Dorey, R.S. and Mayne, V. (1986) Break-dancing injuries. *The Medical Journal of Australia* **144**, 610-611.
- Escher, S.A. (1997) Ulnar diaphyseal stress fracture in a bowler. *The American Journal of Sports Medicine* **25**, 412-413.
- Gearhart, J.P. and Lowe, F.C. (1986) Genitourinary injuries secondary to break dancing in children and adolescents. *Pediatrics* **77**, 922-924.
- Goscienski, P.J. and Luevanos, L. (1984) Injury caused by 'break dancing'. *The Journal of the American Medical Association* **252**, 3367.
- Hamilton, H.K. (1984) Stress fracture of the diaphysis of the ulna in a body builder. *The American Journal of Sports Medicine* **12**, 405-406.
- Ihmeidan, I.H., Tehranzadeh, J., Oldham, S.A., Mnaymneh, W. and Mnaymneh, L.G. (1987) Case report 443. Florid cortical and periosteal reactions due to stress fractures of the right femur and left calcaneus in a "break dancer". *Skeletal Radiology* **16**, 581-583.
- Johnson, S.R. and Jones, D.G. (1986) Break dancing: the need for supervision. *British journal of sports medicine* **20**, 91.
- Joondeph, B.C., Spigelman, A.V. and Pulido, J.S. (1986) Ocular trauma from break dancing. *Archives of Ophthalmology* **104**, 176-177.
- Lee, K.C. and Clough, C. (1990) Intracerebral hemorrhage after break dancing. *The New England Journal of Medicine* **323**, 615-616.
- McBride, D.Q., Lehman, L.P. and Mangiardi, J.R. (1985) Break-dancing neck. *The New England Journal of Medicine* **312**, 186.
- McNeil, S.L., Spruill, W.A., Langley, R.L., Shuping, J.R. and Leonard, J.R. (1987) Multiple subdural hematomas associated with breakdancing. *Annals of Emergency Medicine* **16**, 114-116.
- Moses, J. and Shannon, M. (1985) Back pain, vomiting after break-dance mishap. *Hospital practice* **20**, 100K-100L, 100P.
- Nakamura, T., Yabe, Y., Horiuchi, Y. and Yamazaki, N. (1999) In vivo motion analysis of forearm rotation utilizing magnetic resonance imaging. *Clinical Biomechanics* **14**, 315-320.
- Nakamura, T., Yabe, Y., Horiuchi, Y., Seki, T. and Yamazaki, N. (2000) Normal kinematics of the interosseous membrane during forearm pronation-supination--a three-dimensional MRI study. *Hand Surgery* **5**, 1-10.
- Petschnig, R., Wurnig, C., Rosen, A. and Baron, R. (1997) Stress fracture of the ulna in a female table tennis tournament player. *Journal of Sports Medicine and Physical Fitness* **37**, 225-227.
- Ramirez, B., Masella, P.A., Fiscina, B., Lala, V.R. and Edwards, M.D. (1984) Breaker's neck. *The Journal of the American Medical Association* **252**, 3366-3367.
- Rettig, A.C. (1983) Stress fracture of the ulna in an adolescent tournament tennis player. *The American Journal of Sports Medicine* **11**, 103-106.
- Sharma, V., Knapp, J.K., Wasserman, G.S., Walsh, I. and Hoover, C.J. (1986) Injuries associated with break dancing. *Pediatric Emergency Care* **2**, 21-22.
- Tanabe, S., Nakahira, J., Bando, E., Yamaguchi, H., Miyamoto, H. and Yamamoto, A. (1991) Fatigue fracture of the ulna occurring in pitchers of fast-pitch softball. *The American Journal of Sports Medicine* **19**, 317-321.
- Wheeler, R.E. and Appell, R.A. (1984) Differential diagnosis of scrotal pain after break dancing. *The Journal of the American Medical Association* **252**, 3366.
- Winslet, M.C., Clarke, N.M. and Mulligan, P.J. (1986) Breakdancer's thumb--partial rupture of the ulnar collateral ligament with a fracture of the proximal phalanx of the thumb. *Injury* **17**, 201-202.

Key points

- Stress fractures should not be ignored when the patient changes exercise loading.
- A thoroughly detailed clinical history, physical examination, and plain radiographs were used diagnostically in this clinical case.
- The best methods for the treatment of stress fractures include readjustment training protocols to prevent conversion to overt fractures.

AUTHOR BIOGRAPHY



Yu-Hsu CHEN

Employment

Department of Orthopaedics, Tri-Service General Hospital, Taiwan (R.O.C)

Degree

MD

Research interests

Trauma, tissue engineering.

E-mail: m820570@ndmctsgh.edu.tw

Chun-Lin KUO

Employment

Department of Orthopaedics, Tri-Service General Hospital, Taiwan (R.O.C)

Degree

MD

Research interests

Trauma.

E-mail: doc95035@yahoo.com.tw

Leou-Chyr LIN

Employment

Department of Orthopaedics, Tri-Service General Hospital, Taiwan (R.O.C)

Degree

MD

Research interests

Sport medicine

Shyu-Jye WANG

Employment

Department of Orthopaedics, Tri-Service General Hospital, Taiwan (R.O.C)

Degree

MD

Research interests

Trauma.

E-mail: reoulioushu@yahoo.com.tw



Chian-Her LEE

Employment

Department of Orthopaedics, Tri-Service General Hospital, Taiwan (R.O.C)

Degree

MD

Research interests

Sport medicine.

E-mail: chianherlee@yahoo.com.tw

✉ Chian-Her Lee

Department of Orthopaedics, Tri-Service General Hospital, No. 325, Sec.2, Chenggong Rd., Neihu District, Taipei City, Taiwan (R.O.C)