

Case Report

Stress fracture of the first rib in a high school weight lifter

Hiroyuki Fujioka¹✉, Takeshi Kokubu², Takeshi Makino², Issei Nagura², Narikazu Toyokawa², Atsuyuki Inui², Ryosuke Sakata² and Masahiro Kurosaka²

¹ Department of Orthopaedic Surgery, Hyogo College of Medicine, Nishinomiya, Japan, ² Department of Orthopaedic Surgery, Kobe University Graduate School of Medicine, Kobe, Japan

Abstract

A 17-year-old boy, who played a weight lifting in high school, sustained stress fracture of the first rib without any causes. We successfully treated first rib stress fracture with limitation of using the upper extremity and with using low-intensity pulsed ultrasound.

Key words: Stress fracture, low-intensity pulsed ultrasound, first rib, weight lifting.

Introduction

Stress fracture of the first rib, which is an uncommon cause of shoulder pain and atypical chest pain, is seen in athletes (Sik et al., 2009). Several cases of stress fractures of the first rib have also been reported as sports-related injury, such as baseball, tennis, soccer, ballet dancer, and weight lifting (Coris and Higgins, 2005; Matsumoto et al., 2003; Mikawa and Kobori, 1991; Mithöfer and Giza, 2004; Prisk and Hamilton, 2008). In these sports, the players play elevating their upper extremities and the main cause of stress fracture has been understood as repetitive muscle action and overuse of the upper extremities. We present a rare case of stress fracture of the first rib bone in a weight lifting player at high school and treated the patient with limitation of using the upper extremity and with using low-intensity pulsed ultrasound (LIPUS). The patient and his family were informed that data from the case would be submitted for publication, and gave their consent.

Case Report

A 17-year-old boy gradually felt pain on left shoulder and scapula region without any history of major trauma, when he played a weight lifting. He reduced the sports activities but the symptom was not improved. He visited us four months after he felt pain at first.

On physical examination, there is no muscle atrophy of the shoulder girdle and the upper extremity. Although there was neither rest pain nor sensory disturbance, tenderness was detected at the supraclavicular fossa. Active range of motion of the shoulder was not limited. A radiographic examination showed an apparent fracture line with no callus formation in the middle of the left first rib (Figure 1A). We diagnosed the patient with ununited stress fracture of the first rib and instruct the patient to stop all sports activities using the left upper

extremity. In addition, treatments with LIPUS to the fracture site of the first rib using SAFHS (Sonic Accelerated Fracture Healing System, Teijin Pharma Ltd., Tokyo, Japan) for 20 minutes a day. The ultrasound device consisted of three components: a plastic retention and alignment fixture, a battery-operated treatment head module that applied the ultrasound signal to the skin at the site of the fracture, and a main operating unit. It was operated with a 100-volt alternating current and the ultrasound signal consisted of a 200 µsec burst sine wave of 1.5 MHz repeating at 1.0 kHz. The intensity was 30 mW/cm² spatial average and temporal average. Exposure to LIPUS had been performed for 6 months and the fracture site was bridged by callus formation on the radiographs (Figure 1B). One year after the onset of pain, he was free from symptoms and could return to the original level of his sports activities. He was still free from pain at the shoulder during weight lifting at the latest follow-up two years after initial onset.

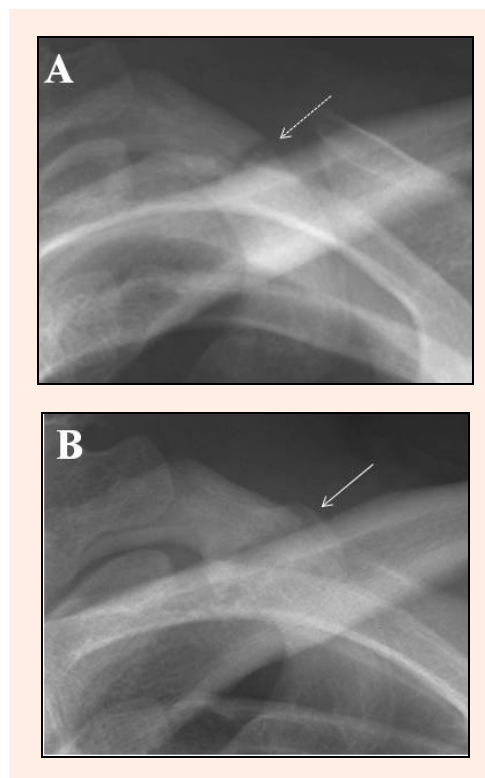


Figure 1. Radiographs of the first rib. Anteroposterior view at the first visit (A) and at 10 months after the onset (B). The broken arrow in (A) indicates the fracture site and the arrow in (B) indicates the bridging callus and fracture union.

Discussion

Fracture of the rib is usually caused by high energy impact and direct trauma. Fracture of the first rib is seen associated with fracture of the clavicle and the scapula, however, an isolated fracture of the first rib is uncommon disorder.

Stress fracture of the first rib has been reported as sports related injury and its main cause of a stress fracture has been understood as repetitive muscle action and overuse of the upper extremities. The first rib has characteristic anatomic features: short, thick, wide, parallel to the transverse plane of the body, having the groove of the subclavian artery and vein, and protected by the clavicle, the scapula, and the adjacent muscles. Two groove of the subclavian artery and vein was considered to be the weakest point of the otherwise strong broad first rib (Coris and Higgins, 2005; Prisk and Hamilton, 2008). Moreover, eccentric contraction of the muscles attaching to the first rib is also considered to be one of the etiology of first rib stress fracture (Coris and Higgins, 2005; Matsumoto et al., 2003; Prisk and Hamilton, 2008). The muscles attaching to the first rib are the scalenus anterior, the scalenus medius, the serratus anterior, and the intercostales. In these muscles, only the serratus anterior attaches to the scapula and directly related to the motion of the upper extremity. The scalenus anterior muscle pulls the lateral portion of the first rib proximally and posteriorly and the scalenus medius muscle pulls the medial portion of the first rib proximally and medially. The serratus anterior muscle inserting on the inferior surface of the first rib pulls posterolaterally and inferiorly. It is considered that repetitive contraction of these muscles in vigorous sports activities using the upper extremity cause the shearing force at the groove of the subclavian vessels and result in stress fracture.

Previous reports showed that modification of activity and rest are usually sufficient for treatment of stress fractures of the first rib (Coris and Higgins, 2005; Matsumoto et al., 2003; Mithöfer and Giza, 2004; Prisk and Hamilton, 2008). By contrast, complications such as nonunion and plexus brachialis palsy have been reported in a few cases of first rib fracture (Edwards and Murphy, 2001; Ochi et al., 1994; O'Neal et al., 2009; Proffer et al., 1991). In the present case, the onset of pain was gradual and the symptoms had continued for four months. The radiograph at the first visit to our hospital clearly showed nonunion of the first rib without callus formation. We considered that rest and limitation of sports activities would not be sufficient to obtain union of the first rib. Therefore, we used LIPUS treatment in addition to limitation of athletic activity.

A basic investigation of LIPUS in fracture healing showed that LIPUS increased the strength of the fracture callus and aggrecan gene expression in a rat fracture model and initiated bone healing in a rat fracture nonunion model (Takikawa et al., 2001; Wang et al., 1994; Yang et al., 1996). In prospective, randomized, and double-blind clinical studies, LIPUS accelerate the healing of fractures of the distal radius and the tibia (Heckman et al., 1994; Kristiansen et al., 1997). Fujioka et al. demonstrated successful treatment of nonunion of the hook of

the hamate with LIPUS (Fujioka et al., 2000). These prior basic and clinical researches suggest that LIPUS accelerates the repair process of nonunion as well as that of normal fracture.

Conclusion

We reported a rare case of ununited stress fracture of the first rib and successfully treated first rib stress fracture with limitation of using the upper extremity and with LIPUS treatment.

References

- Coris, E.E. and Higgins 2nd, H.W. (2005) First rib stress fractures in throwing athletes. *American Journal of Sports Medicine* **33**, 1400-1404.
- Edwards, T.B. and Murphy, C. (2001) Nonunion of a dominant side first rib stress fracture in a baseball pitcher. *Orthopedics* **24**, 599-600.
- Fujioka, H., Tsunoda, M., Noda, M., Matsui, N. and Mizuno, K. (2000) Treatment of ununited fracture of the hook of the hamate by low-intensity pulsed ultrasound. -A case report-. *Journal of Hand Surgery (American volume)* **25**, 77-79.
- Heckman, J.D., Ryaby, J.P., McCabe, J., Frey, J.J. and Kilcoyne, R.F. (1994) Acceleration of tibial fracture-healing by non-invasive, low-intensity pulsed ultrasound. *Journal of Bone and Joint Surgery (American volume)* **76**, 26-34.
- Kristiansen, T.K., Ryaby, J.P., McCabe, J., Frey, J.J. and Roe, L.R. (1997) Accelerated healing of distal radial fractures with the use of specific, low-intensity ultrasound: a multicenter, prospective, randomized, double-blind, placebo-controlled study. *Journal of Bone and Joint Surgery (American volume)* **79**, 961-973.
- Matsumoto, T., Fujita, K., Fujioka, H., Tsunoda, M., Yoshiya, S., Kurosaka, M. and Mizuno, K. (2003) Stress fracture of the first rib in a soccer player: A rare etiology of shoulder pain. *Journal of Shoulder and Elbow Surgery* **12**, 197-199.
- Mikawa, Y. and Kobori, M. (1991) Stress fracture of the first rib in a weight lifter. *Archives Orthopaedic Trauma Surgery* **110**, 121-122.
- Mithöfer, K. and Giza, E. (2004) Pseudarthrosis of the first rib in the overhead athlete. *British Journal of Sports Medicine* **38**, 221-222.
- Ochi, M., Sasashige, Y., Murakami, T. and Ikuta, Y. (1994) Brachial plexus palsy secondary to stress fracture of the first rib. Case report. *Journal of Trauma* **36**, 128-130.
- O'Neal, M., Ganey, T.M. and Ogdan, J.A. (2009) First rib stress fracture and pseudarthrosis in the adolescent athlete: The role of cost-sternal anatomy. *Clinical Journal of Sports Medicine* **19**, 65-67.
- Prisk, V.R. and Hamilton, W.G. (2008) Stress fracture of the first rib in weight-trained dancers. *American Journal of Sports Medicine* **36**, 2444-2447.
- Proffer, D.S., Patton, J.J. and Jackson, D.W. (1991) Nonunion of a first rib fracture in a gymnast. *American Journal of Sports Medicine* **19**, 198-201.
- Sik, E.C., Batt M.E. and Heslop, L.M. (2009) Atypical chest pain in athletes. *Current Sports Medicine Report* **8**, 52-58.
- Takikawa, S., Matsui, N., Kokubu, T., Tsunoda, M., Fujioka, H., Mizuno, K. and Azuma, Y. (2001) Low-intensity pulsed ultrasound initiates bone healing in rat nonunion fracture model. *Journal of Ultrasound Medicine* **20**, 197-205.
- Wang, S.J., Lewallen, D.G., Bolander, M.E., Chao, E.Y., Ilstrup, D.M. and Greenleaf, J.F. (1994) Low intensity ultrasound treatment increases strength in a rat femoral fracture model. *Journal of Orthopaedic Research* **12**, 40-47.
- Yang, K.H., Parvizi, J., Wang, S.J., Lewallen, D.G., Kinnick, R.R., Greenleaf, J.F. and Bolander, M.E. (1996) Exposure to low-intensity ultrasound increases aggrecan gene expression in a rat femur fracture model. *Journal of Orthopaedic Research* **14**, 802-809.

Key points

- Stress fracture of the first rib in a weight lifter was successfully treated with limitation of sports activity and with LIPUS treatment.

AUTHOR BIOGRAPHY



Hiroyuki FUJIOKA

Employment

Department of Orthopaedic Surgery,
Hyogo College of Medicine, Nishinomiya,
Japan

Degree

MD

Research interests

General orthopaedics, hand surgery, sports
medicine.

E-mail: hfujioka@hyo-med.ac.jp

✉ **Hiroyuki Fujioka, MD**

Department of Orthopaedic Surgery, Hyogo College of Medicine, 1-1 Mukogawa-cho, Nishinomiya, 663-8501, Japan.