

Case report

Subcutaneous peroneus longus tendon rupture associated with os peroneum fracture

Hiroyuki Fujioka¹✉, Takeshi Kokubu², Takeshi Makino², Issei Nagura², Toshihisa Maeda², Masahiro Kurosaka², Hiroaki Okuno¹, Tokuyoshi Yamagiwa¹, Juichi Tanaka¹ and Shinichi Yoshiya¹

¹Department of Orthopaedic Surgery, Hyogo College of Medicine, Nishinomiya, Japan, ²Department of Orthopaedic Surgery, Kobe University Graduate School of Medicine, Kobe, Japan

Abstract

We report a rare case of subcutaneous peroneus longus tendon rupture associated with os peroneum fracture. Three dimensional computed tomographic scan was useful to understand this disorder. We treated the patient with excision of fractured os peroneum and tenodesis of the proximal stump of the ruptured peroneus longus tendon to the lateral aspect of the calcaneus.

Key words: Os peroneum, fracture, rupture, peroneus longus tendon

Introduction

Subcutaneous tendon rupture of the peroneus longus tendon is rare disorder compared with tendinopathy of the peroneus longus tendon in sport activities. The peroneus longus tendon is most susceptible to injury at the cuboid notch because of the sharp change in direction of the tendon as it courses toward its insertion on the first ray. As a result, an intratendinous, fibrocartilaginous thickening or sesamoid (os peroneum) forms at the cuboid notch to shield the peroneus longus from the increased force at this location (Coughlin, 1999; Sammarco, 1994). Os peroneum is located in the distal portion of the peroneus longus tendon adjacent to the lower border of the cuboid bone. Direct and indirect trauma to the foot, such as extreme inversion, plantar or dorsal flexion of the foot associated with contraction of the peroneus longus muscle may cause uncommon subcutaneous rupture of the peroneus longus tendon associated with fracture of the os peroneum (Bessette and Hodge, 1998; MacDonald and Wertheimer, 1997; Peacock et al., 1986; Pessina, 1988; Peterson and Stinson, 1992). We report a rare case of subcutaneous peroneus longus tendon rupture associated with os peroneum fracture and treated with excision of fractured os peroneum and tenodesis of the proximal stump of the peroneus longus tendon to the lateral aspect of the calcaneus. The patient and his families were informed that data from the cases would be submitted for publication and gave their consent.

Case report

A 67-year-old man sprained his left foot, in a position of inversion and plantar flexion, in hitting the ball at the steep surface when he was playing golf. He felt severe

pain of the lateral aspect of the left foot but he was able to walk and to bear weight with pain. He consulted a primary care doctor and was transferred to our hospital two weeks after injury. On physical examination, diffuse swelling and tenderness were detected on the lateral aspect of the left foot. There were no neurovascular complications of the foot and toes.

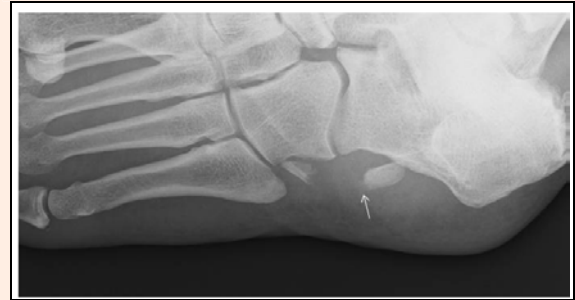

Figure 1. Radiograph of the foot. Fracture of the os peroneum was detected on oblique view.

The radiograph showed a displaced fracture of the os peroneum (Figure 1). In the three dimensional reconstruction computed tomographic (3D-CT) scan by combining multiplanar reconstructions (MPR) and volume-rendering technique (VRT), the distal fragment of the fractured os peroneum remained at the cuboid notch and the proximal fragment displaced proximally by traction of the peroneus longus tendon (Figure 2). We diagnosed the patient with subcutaneous rupture of the peroneus longus tendon associated with os peroneum fracture and treated the patient surgically under general anesthesia.

The patient was placed the lateral position. A curvilinear incision was made directly over the peroneal tendons from the fibular malleolus to the fifth metatarsal base and the peroneal sheath and inferior peroneal retinaculum were incised. The peroneus longus tendon rupture with the fractured os peroneum was detected at the peroneal tubercle. The large ossicle encompassed the entire width of the proximal stump of the ruptured peroneus longus tendon (Figure 3). The distal fragment of the fractured os peroneum was detected at the cuboid notch. The peroneus brevis tendon was not injured. Because the displaced fractured os peroneum could not be reduced, the proximal fragment of the os peroneum was excised. Additionally, the proximal tendon stump was attached to the

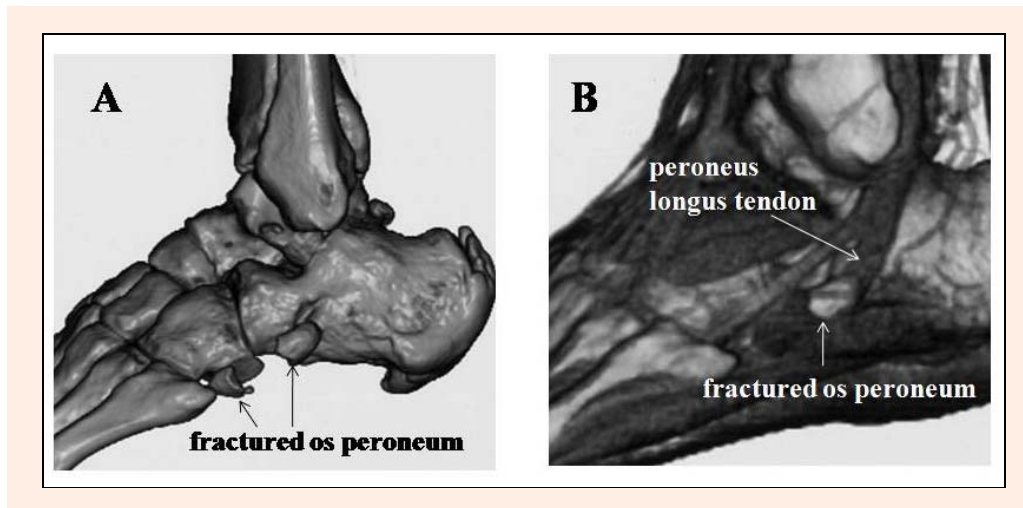


Figure 2. 3D-CT of the foot. Displaced fracture of the os peroneum was demonstrated on MPR 3D-CT (A) and the proximal fragment of the fractured os peroneum was retracted proximally retained with the proximal tendon stump of the peroneus longus tendon (B).

lateral aspect of the calcaneus using the suture anchor (Mini Quick Anchor System Plus, Mitek Surgical Products, Inc., MA, USA) inserted to the calcaneus. The distal tendon stump of the ruptured peroneus longus tendon and the distal fragment of the os peroneum were left untreated.

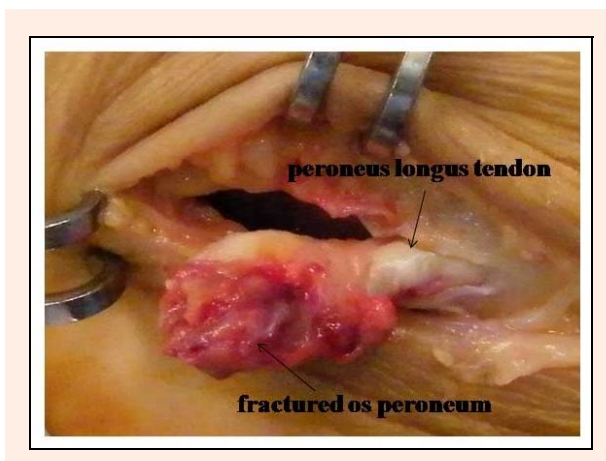


Figure 3. Intraoperative finding. The proximal fragment of the fractured os peroneum was retracted proximally retained with the proximal tendon stump of the peroneus longus tendon.

After surgery, the patient was allowed to walk without weight bearing with a short leg cast for 2 weeks. An additional 2 weeks, the patient walked with partial weight bearing without immobilization. One month after surgery, the patient was able to walk with full weight bearing and he could return to the original sports activity level at postoperative three months. One year after surgery, the patient had neither complaints nor symptoms and he could walk and play golf without pain.

Discussion

The os peroneum is an accessory ossicle located within the substance of the peroneus longus tendon and its loca-

tion, size, and appearance are varied (Coughlin, 1999). Because of variable ossification centers, the ossicle may present bipartite and multipartite which may mimic fracture lines on the radiographs. A partite os peroneum may be misdiagnosed as fracture and the diagnosis of fracture of the os peroneum may be difficult. Biltz demonstrated the usefulness of magnetic resonance imaging (MRI) to diagnose the retracted fractured os peroneum retained within the peroneus longus tendon (Biltz, 2007). By contrast, 3D-CT is applied for evaluation of tendons of foot and hand and 3D-CT is useful for surgical planning and patient education (Choplin et al., 2004; Sunagawa et al., 2005). In the present case, 3D-CT clearly demonstrated both distal and proximal fragments of the fractured os peroneum and the retracted fractured os peroneum retained within the peroneus longus tendon. We think that 3D-CT has an advantage of visualizing the disorders of tendon and bone simultaneously in three dimension compared with MRI.

Subcutaneous tendon rupture of the peroneus longus tendon could be caused by direct and indirect trauma to the foot, such as extreme inversion, plantar or dorsal flexion of the foot associated with contraction of the peroneus longus muscle in sports activities. The peroneus longus tendon is most susceptible to injury at the cuboid notch because of the sharp change in direction of the tendon as it courses toward its insertion on the first ray. Therefore, acute rupture of the peroneus longus tendon could occur associated with fracture of the os peroneum. (MacDonald and Werthimer, 1997; Peacock et al., 1986; Pessina, 1988; Peterson and Stinson, 1992; Sammarco, 1994).

To repair and reconstruct acute rupture of the peroneus longus tendon, Peacock et al. (1986) reported primary repair of an os peroneum fracture by weaving non-absorbable suture through the ossicle and tendon. Biltz and Nemes (2007) reported that the peroneus longus transfer to the peroneus berris tendon above the ankle joint after excision of the fracture ossicle of os peroneum was successful.

However, repairing peroneus longus ruptures at the

cuboid notch, with or without the presence of an os peroneum, is difficult because it is not easy to access the distal stump of the tendon deep in the midfoot. Moreover, peroneus longus rupture with the displaced fracture of os peroneum is a more challenging situation. Conservative treatment with immobilization or excision of the fractured os peroneum is one of the options for treatment of os peroneum fracture (MacDonald and Werthimer, 1997; Pessina, 1988; Peterson and Stinson, 1992; Sammarco, 1994). In the present case, the proximal fragment of the os peroneum was excised and additionally the proximal tendon stump was attached to the lateral aspect of the calcaneus using the suture anchor. The main aim of our surgical procedure was the excision of the fractured os peroneum to relieve foot pain.

Conclusion

We present a rare case of subcutaneous peroneus longus tendon rupture associated with os peroneum fracture. 3D-CT is one of the useful methods to diagnose subcutaneous peroneus longus tendon rupture associated with os peroneum fracture and surgical excision of the fractured os peroneum is one of the good treatment options. Subcutaneous peroneus longus tendon rupture and os peroneum fracture can be caused by the similar mechanism of ankle sprain and the physicians should be aware of this disorder.

References

- Bessette, B.J. and Hodge, J.C. (1998) Diagnosis of the acute os peroneum fracture. *Singapore Medical Journal* **39**, 326-327.
- Biltz, N.M. and Nemes, K.K. (2007) Bilateral peroneus longus tendon rupture through a bipartite os peroneum. *Journal of Foot and Ankle Surgery* **46**, 270-277.
- Choplin, R.H., Buckwalter, K.A., Rydberg, J. and Farber, J.M. (2004) CT with 3D rendering of the tendons of the foot and ankle: technique, normal anatomy, and disease. *Radiographics* **24**, 343-356.
- Coughlin, M.J. (1999) Sesamoids and accessory bones of the foot. In: *Surgery of the foot and ankle*. Ed: Coughlin MJ and Mann RA. 7th edition. St. Louis, Mosby. 437-499
- MacDonald, B.D. and Wertheimer, S.J. (1997) Bilateral os peroneum fractures: Comparison of conservative and surgical treatment and outcomes. *Journal of Foot Ankle Surgery* **36**, 220-225.
- Peacock, K.C., Resnick, E.J. and Thoder, J.J. (1986) Fracture of the os peroneum with rupture of the peroneus longus tendon. *Clinical Orthopaedics and Related Research* **202**, 223-226.
- Pessina, R. (1988) Os peroneum fracture. A case report. *Clinical Orthopaedics and Related Research* **227**, 261-264.
- Peterson, D.A. and Stinson, W. (1992) Excision of the fractured os peroneum: A report on five patients and review of the literature. *Foot and Ankle* **13**, 277-281.
- Sammarco, G.J. (1994) Peroneal tendon injuries. *Orthopaedic Clinics of North America* **25**, 135-145.
- Sunagawa, T., Ishida, O., Ishiburo, M., Suzuki, O., Yasunaga, Y. and Ochi, M. (2005) *Journal of Computer Assisted Tomography* **29**, 94-98.

Key points

- In order to understand a rare case of subcutaneous peroneus longus tendon rupture associated with os peroneum fracture, three dimensional computed tomographic scan was useful.
- The patient was treated with excision of fractured os peroneum and tenodesis of the proximal stump of the ruptured peroneus longus tendon to the lateral aspect of the calcaneus.

AUTHORS BIOGRAPHY



Hiroyuki FUJIOKA

Employment

Lecturer

Degree

MD

Research interest

Orthopaedics, Hand, Upper extremity, Sports, Basic research.

E-mail: hfujioka@hyo-med.ac.jp



Takeshi KOKUBU

Employment

Assistant professor

Degree

MD

Research interest

Orthopaedics, Shoulder, Sports, Basic research.

Takeshi MAKINO

Employment

Assistant professor

Degree

MD

Research interest

Orthopaedics, hand, upper extremity, sports, basic research.

Issei NAGURA

Employment

Physician

Degree

MD

Research interest

Orthopaedics, upper extremity, sports, basic research.

Toshihisa MAEDA

Employment

Physician

Degree

MD

Research interest

General orthopaedics

Masahiro KUROSAKA

Employment

Professor, Chairman

Degree

MD

Research interest

Orthopaedics, knee, sports, basic research.



Hiroaki OKUNO

Employment

Assistant professor

Degree

MD

Research interest

Orthopaedics, hand, sports, basic research.

**Tokuyoshi YAMAGIWA****Employment**

Assistant professor

Degree

MD

Research interest

Orthopaedics, hand, sports.

E-mail: yamagiwa@hyo-med.ac.jp**Juichi TANAKA****Employment**

Professor

Degree

MD

Research interest

Orthopaedics, hand, sports.

Shinichi YOSHIYA**Employment**

Professor, Chairman

Degree

MD

Research interest

Orthopaedics, knee, sports.

✉ Hiroyuki Fujioka

Department of Orthopaedic Surgery, Hyogo College of Medicine, 1-1, Mukogawa-cho, Nishinomiya, 663-8501 Japan