

Case report

## Bilateral volleyball-related deformity of the little fingers: mallet finger and clinodactyly mimic

Mustafa Uslu <sup>1</sup>✉, Kazim Solak <sup>1</sup>, Mustafa Ozsahin <sup>2</sup> and Hakan Uzun <sup>3</sup>

<sup>1</sup>Department of Orthopaedics and Traumatology, <sup>2</sup>Department of Physical Medicine and Rehabilitation, and <sup>3</sup>Department of Pediatrics, Duzce University School of Medicine, Duzce, Turkey

### Abstract

A 14-year-old male high school volleyball player was seen to evaluate right- and left-hand little-finger distal interphalangeal joint deformity and pain. His symptoms began during his second season of competitive play. The distal interphalangeal (DIP) joints of the little fingers flexed 20–30°, and a 10–15° valgus deformity was seen at the same joints. Pain was relieved with rest but returned immediately after playing volleyball, so plain radiographs were obtained. The flexion and valgus deformity was obvious on plain radiographs and through a clinical examination. Thus, a bilateral little-finger distal phalanx base epiphysis injury was seen. This injury is characterized by a biplanar Salter-Harris physal injury; type 5 on anteroposterior radiographs and type 2 on lateral plain radiographs. The deformity occurred as a result of competitive volleyball play. To our knowledge, this is the first reported case of a bilateral biplanar physal injury of the base of distal phalanges of the little fingers. Flexion and valgus deformities of DIP joints are a result of repeated micro traumas around the physis.

**Key words:** Bilateral little-finger deformity, mallet finger, clinodactyly, volleyball sport injury, physis injury, hand pain.

### Introduction

Volleyball is one of the most popular team sports and presents several possible mechanisms for injury to the player. Common volleyball injuries have been described at length in recent years (Bahr and Bahr, 1997; Bahr and Reeser, 2003). Most injuries to volleyball players occur in the lower extremities, particularly the foot and ankle. Although injuries to the hand and wrist are common in volleyball players, most go unreported (Briner and Kacmar, 1997). Among the injuries to the hands, fingers are involved in almost half of the cases. Sprains or strains are the most common type of injury (Bhairi and Nijsten, 1992), and epiphysal injuries of the hand are less common. The epiphysis of the distal phalanges begins to ossify at 12 to 36 months of age and closes at approximately

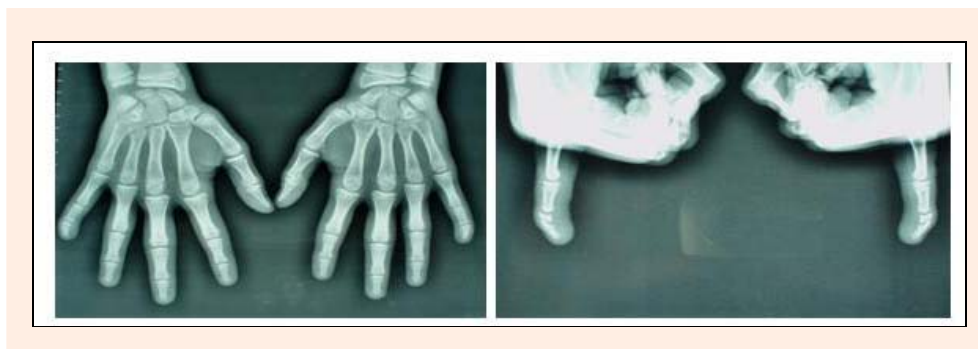
13 to 16 years (Hensinger, 1986). Prior to closure of the epiphysis, fractures (Salter-Harris type I or II) usually occur through the growth plate or through the juxtaepiphyseal region 1 to 2 mm distal to the growth plate. The extensor tendon inserts into the epiphysis only, whereas the flexor digitorum profundus inserts into the metaphysis or spans both the epiphysis and the metaphysis (Al-Qattan, 1998). Because of the asymmetry of these tendon insertions, the clinical manifestation of this injury in the young mimics a mallet finger and a clinodactyly deformity. A flexion deformity is the result of a Salter-Harris type II injury, whereas a valgus deformity of the distal phalanges is the result of a Salter-Harris type V injury on the radial side of the physis.

### Case report

A 14-year-old male high school student who had played volleyball for 3 years presented with a complaint of right- and left-hand little-finger flexion, valgus deformity (Figure 1), and pain. These symptoms began during his second season of competitive play. His role was a setter and passer on the team. The patient initially complained of pain in the distal phalanges of the little fingers, but he continued to play. As he continued to compete, he began to note the onset of flexion and a valgus deformity of the distal interphalangeal (DIP) joints. Plain radiographs and a hand examination were performed, and the flexion and valgus deformity were obvious on plain radiographs as well as on his clinic examination. A bilateral little-finger distal phalanx base epiphysis injury was seen. This injury is characterized by a biplanar Salter-Harris physal injury, type V on anteroposterior radiographs and type II on lateral plain radiographs (Figure 2). The wrist, hand, and other fingers were normal. As the pain persisted, he was provided with bilateral little-finger splints. Control plain radiographs were taken with finger splints and the patient was instructed to abstain from play until physal closure.

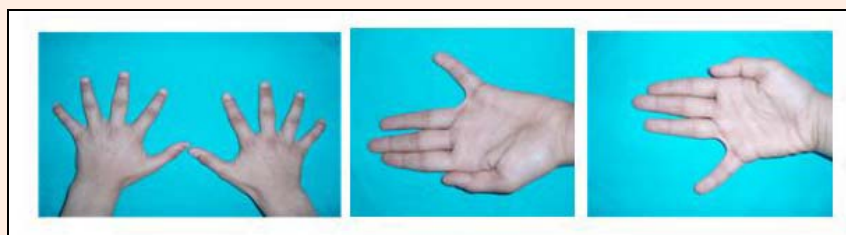

Figure 1. Bilateral little-finger distal interphalangeal joint flexion and valgus deformities.



**Figure 2.** Plain anteroposterior and lateral radiographies of the little fingers on both hands.

## Discussion

This was an unusual case related to a volleyball injury. Particular injuries are seen in young volleyball players. Compared with other sports (handball, soccer, basketball, and badminton), volleyball players have a higher frequency of injuries to the hands, fingers, and ankles, but fewer injuries located in other anatomical regions (Solgard et al., 1995). It is highly significant that school/educational players have more hand and finger injuries than do club players (Solgard et al., 1995). Our case was a school volleyball player. As most of the injuries are the result of acute trauma, repeated long-term injuries are seen rarely. The hand and finger injuries occur during contact with the ball in the overhand pass position, and only a few occur while blocking or spiking. High-level club players incur non-contact injuries during jumping, and young players are generally injured by contact with the ball, mostly during overhand passing. In this case, the little-finger physeal injuries were thought to have occurred as a result of repeated trauma by contact with the ball during overhand passing, resulting in a Salter-Harris type V injury on the anteroposterior planes and a Salter Harris type II injury on the lateral planes. Thus, a flexion and valgus deformity occurred in the little-finger DIP joints. We had to exclude the possibility that this was a result of direct trauma to the upper extremities, which may cause vascular injuries leading to ischemia of the hand and fingers such as hypothenar hammer syndrome (Reekers and Koedam, 1998; Marie et al., 2007). In this case, the pathology was bilateral, and the patient examination did not support hypothenar hammer syndrome. Angiography must be performed to exclude microemboli in the digital arteries of the hand. This fracture pattern also mimics Seymours' fracture, but it is caused by direct trauma to the distal phalanges physis, resulting in an open fracture. There is usually a transverse laceration of the nail matrix, with the base of the nail itself extruding out from under the nail fold (Seymour, 1966). Premature closure of the epiphysis secondary to infection rather than direct injury to the growth plate was excluded (Engber and Clancy, 1978). We observed no infection or signs of premature epiphyseal closure in this case.

## Conclusion

Salter-Harris injuries of the distal phalanx of the fingers in young volleyball players may at first appear to be the

result of acute direct trauma. These injuries are almost always associated with physical injuries leading to deformities. Here, we presented an unusual case with a bilateral biplanar physical injury to the base of the little-finger distal phalanx. Flexion and valgus deformities of the DIP joints were present as a result of repeated micro traumas to the physical region. Sports injuries to the hand often require treatment in orthopedic departments to avoid permanent deformities. Short- or long-term functional results can be gained by simple splinting procedures and abstention from play.

## References

- Al-Qattan, M.M. (1998) An unusual Salter type 2 fracture of the distal phalanx. *Journal of Hand Surgery [Br]* **23**, 283-284.
- Bahr, R. and Bahr, I.A. (1997) Incidence of acute volleyball injuries: a prospective cohort study of injury mechanisms and risk factors. *Scandinavian Journal of Medical Sciences and Sports* **7**, 166-171.
- Bahr, R. and Reeser, J. (2003) Injuries among world-class professional beach volleyball players. *American Journal of Sports Medicine* **31**, 119-125.
- Bhairon, N. and Nijsten, M. (1992) Hand injuries in volleyball. *International Journal of Sports Medicine* **13**, 351-354.
- Briner, W.W. Jr. and Kacmar, L. (1997) Common injuries in volleyball: mechanisms of injury, prevention and rehabilitation. *Sports Medicine* **24**, 65-71.
- Engber, W.D. and Clancy, W.G. (1978) Traumatic avulsion of the finger nail associated with injury to the phalangeal epiphyseal plate. *Journal of Bone and Joint Surgery [Am]* **60**, 713-714.
- Hensinger, R.N. (1986) *Standards in Pediatric Orthopedics*. Raven Press, New York. 136-149.
- Marie, I., Herve, F., Primard, E., Cailleux, N. and Levesque, H. (2007) Long-term follow-up of hypothenar Hammer Syndrome. A series of 47 patients. *Medicine(Baltimore)* **86**(6), 334-343.
- Solgard, L., Nielsen, A.B., Muller-Madsen, B., Jacobsen, B.W., Yde, J. and Jensen, J. (1995) Volleyball injuries presenting in casualty: a prospective study. *British Journal of Sports Medicine* **29**(3), 200-204.
- Reekers, J.A. and Koedam, N. (1998) Volleyball-related ischemia of the hand. *Cardiovascular Interventional Radiology* **21**, 261.
- Seymour, N. (1966) Juxta-epiphyseal fracture of the terminal phalanx of the finger. *Journal of Bone and Joint Surgery [Br]* **48**, 347-349.

## AUTHORS BIOGRAPHY



**Mustafa USLU**

### Employment

Assistant Professor, Düzce University Medical School, Department of Orthopaedics and Traumatology, Turkey

### Degree

MD

### Research interest

Hand and arthroscopic surgery.

**E-mail:** mustafauslu74@hotmail.com

---

**Kazım SOLAK****Employment**

Düzce University Medical School, Department of Orthopaedics and Traumatology, Turkey

**Degree**

MD

**E-mail:** drkazimsolak@hotmail.com

---

**Mustafa ÖZŞAHİN****Employment**

Assistant Professor, Düzce University Medical School, Department of Physical Medicine and Rehabilitation, Turkey

**Degree**

MD

**Research interest**

Orthopaedic rehabilitation.

**E-mail:** drozsahin@hotmail.com

---

**Hakan UZUN****Employment**

Assistant Professor, Düzce University Medical School, Department of Pediatrics, Turkey.

**Degree**

MD

**Research interest**

Pediatric emergency care.

**E-mail:** uzunhakan2003@yahoo.com

---

**Key points**

- As a result of repeated micro traumas to the physial region, flexion and valgus deformities of the distal interphalangeal (DIP) joints should be occurred.
- Sports injuries to the hand often require treatment in orthopedic departments to avoid permanent deformities.
- Short- or long-term functional results can be gained by simple splinting procedures and abstention from play.

**✉ Mustafa Uslu, MD**

Duzce University Medical School, Department of Orthopaedics and Traumatology, Duzce, 81600, Turkey