

Case report

## Trapezoid stress fracture in an international shot-putter: A Case Report

Neil Heron<sup>1,2</sup>✉, Francisco Verdugo<sup>3</sup>, Antonio Turmo<sup>3</sup> and Lluís T. Pérez<sup>3</sup>

<sup>1</sup> Department of General Practice and Primary Care, Queen's University, Belfast, Northern Ireland; <sup>2</sup> Centre for Public Health Research, Queen's University, Belfast, Centre of Excellence for Public Health Research (NI), Northern Ireland; <sup>3</sup> Centre d'Alt Rendiment (CAR, High Performance Centre), Sant Cugat del Valles, Catalonia, Spain

### Abstract

Trapezoid fractures are relatively rare upper limb fractures. The case report of a trapezoid stress fracture in the dominant hand of a 22 year old international standard shot-putter is presented.

**Key words:** Trapezoid, stress fracture.

### Case report

A 22 year old international shot-putter initially presented to the sports medicine clinic in December, 2009 complaining of 1-2 year history of steadily increasing right hand first and second proximal metacarpal pain with no history of trauma. The pain appeared to be particularly provoked on right first and second metacarpal extension and abduction. On examination there was no obvious swelling or deformity and no anatomical snuffbox tenderness. There was however bony tenderness on deep palpation of the proximal first and second metacarpals. Hand and wrist x-rays and bed-side ultrasound imaging were initially negative. The hand x-rays are included in Figure 1.

As no bony or ligament injury was identified, treatment initially included local massage, local anaesthetic injection into the area of tenderness, extracorporeal shock wave therapy and subsequently an injection of platelet-rich plasma (PRP) into the area of maximal tenderness. Due to the failure to respond to treatment, subsequent investigations included a technetium bone scan, which showed increased uptake in the region of the trapezium, trapezoid and first and second metatarsal. A CT scan then showed the lesion more clearly, a stress fracture of the right trapezoid with no ligament disruption (Figure 2).

The patient was initially treated with a thumb spica splint for approximately 8 weeks and magnetic therapy which provided significant symptomatic improvement. He also undertook hand therapy with the physiotherapists, involving stretching and strengthening exercises of the wrist and hand. If the athlete had failed to respond to conservative management, then the next stage would have involved surgical management as discussed by previous authors (Sadowski and Montilla 2008). He is currently asymptomatic and continues to compete as an international standard shot-putter.

### Discussion

The trapezoid is the least commonly fractured carpal

bone, with Sadowski and Montilla (2008) reporting trapezoid fractures to account for 0.4% of all carpal injuries. The trapezoid is infrequently injured due its position within the wrist, situated within strong intercarpal ligaments and between the base of the second metacarpal and carpal bones (Afifi and Lu, 2011). Single-bone traumatic fractures of the trapezoid have been previously reported in the medical press by several authors (Afifi and Lu, 2011; Ekstrand and Torstveit, 2012; Kain and Heras-Palou, 2012; Kam et al., 2011, Miyawaki et al., 2000, Nagumo et al., 2002, Sadowski and Montilla 2008) but this is the first time a stress fracture of the trapezoid has been described.

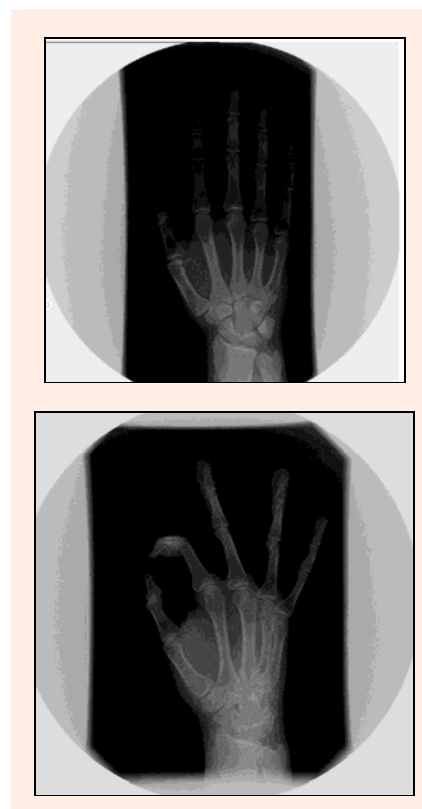
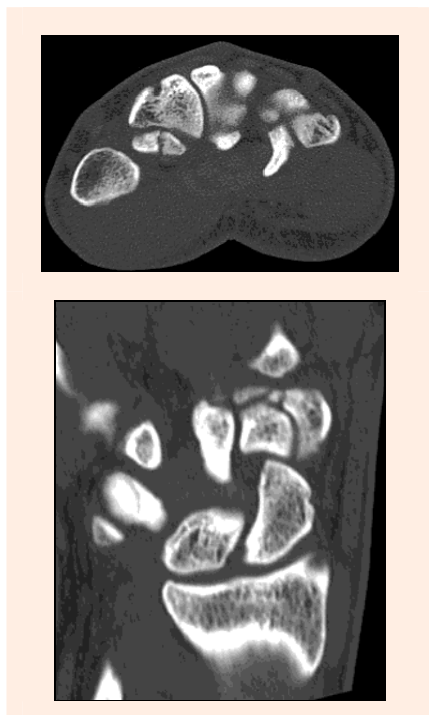


Figure 1. Right hand x-rays.

Stress fractures have classically been divided into fatigue and insufficiency fractures, with our case being categorised under a fatigue fracture (Anderson, 2006). Positive xrays for stress fractures have been reported to be as low as 15% initially (Anderson, 2006). Indeed Afifi and Lu (2011) have previously commented that the overlapping of the carpal bones makes plain radiographs difficult to interpret and this has been supported by previous

authors (Sadowski and Montilla, 2008). Trapezoid fractures often give poor localising signs and symptoms as reported in our athlete and in previous cases (Kain and Heras-Palou, 2012). Thus a high degree of suspicion for trapezoid stress fractures merits further investigation with a bone scan, MRI and/or CT scanning and this statement is supported by Gruson et al. (2008) who advise MRI or CT for imaging of trapezoid fractures after plain x-ray. Indeed Kain and Heras-Palou (2012) reported on 11 traumatic trapezoid fractures and found CT scanning to be the primary mode of diagnosis, accounting for 8 of the diagnoses.



**Figure 2.** Right wrist CT scans.

Sadowski and Montilla (2008) previously described a case of a traumatic trapezoid fracture following a punch which was successfully treated with cast immobilisation for 6 weeks and then a thumb splint for the following 2 weeks. Similarly, our athlete's pain was successfully treated with thumb spica splinting for approximately 8 weeks. Conservative management of trapezoid fractures have also been supported by Gruson et al. (2008) in those fractures that are nondisplaced, with surgical management limited to those with displaced trapezoid fractures or associated carpal injuries.

Sadowski and Montilla (2008) also reported in their traumatic trapezoid fracture that the patient presented with wrist swelling, snuffbox tenderness, reduced range of motion of the wrist and pain at the base of the second metacarpal. Clinical features reported to occur in trapezoid fractures are base of second metacarpal tenderness, anatomical "snuffbox" tenderness or pain on axial loading of the second finger (Afifi and Lu, 2011) although these signs are not universal. Our patient had pain at the base of the 2<sup>nd</sup> metacarpal as well as the 1<sup>st</sup> metacarpal with pain on extension and abduction of these two fingers although no wrist swelling, snuffbox tenderness or re-

duced range of motion. Thus stress trapezoid fractures seem to present slightly differently from traumatic trapezoid fractures although it is difficult to comment further on this with no other case reports in the literature.

The mechanism of traumatic trapezoid injury has been previously reported by Miyawaki et al. (2000) as excessive wrist dorsiflexion, which the authors suggest occurs, "in the same manner that a walnut is broken with nutcrackers." Gruson et al. (2008) also report the mechanism of injury to the trapezoid as an axial load or bending stress. Indeed international shot putts weight 7.26 kg, with the technique requiring significant wrist movement, particularly dorsiflexion, and thus the wrist and carpal bones are placed under considerable forces during this sport. This requires further exploration through, for example biomechanical assessments, to enable sport physicians to gain further knowledge regarding trapezoid fractures.

When a stress fracture is diagnosed, it is important to consider the potential underlying mechanisms for this injury and previous authors have classified these as intrinsic and extrinsic (Pegrum et al., 2012). These risk factors must be considered when taking the history, performing the examination of the athlete with relevant investigations and then corrected as appropriate. Ekstrand and Torstveit (2012) have recently reported on the underlying mechanisms for stress fractures in elite footballers. They report that athletes who sustain a stress fracture tend to be younger. They also report repetitive loading, rapid increases in load and low calorific intake as risk factors. The relevant risk factors for this athlete are his relatively young age and the repetitive loading nature of his sport to the dominant wrist. Thus methods to help reduce the subsequent risk of stress fractures in athletes are ensuring an appropriate diet with no negative energy balance, monitoring training loads with appropriate rest periods, especially in young athletes who are at risk of stress fractures, and introducing diversity into the training regime to avoid overload, particularly of a specific joint like the wrist.

It is also imperative to consider the female athletic triad (Otis et al 1997) (disordered eating, menstrual dysfunction, and osteoporosis) when dealing with this athletic population, which has been proposed to be due to an energy deficit following on from a relatively low energy intake in combination with high energy demands (Ekstrand and Torstveit, 2012).

### Limitations

This is one case report study and further evidence is therefore required into this unique injury and underlying mechanisms for this injury.

### Conclusion

We presented the first case report of a trapezoid stress fracture in the dominant hand of an international-standard shot-putter. The mechanism for traumatic trapezoid fracture has been previously reported to occur with excessive wrist dorsiflexion by Miyawaki et al. (2000) and Gruson et al. (2008). The investigation of choice for trapezoid fractures would appear to be MRI or CT after initial plain

x-rays. Non-displaced isolated trapezoid stress fractures appear to respond well to simple immobilisation. Trapezoid stress fractures should be considered in the differential diagnosis of persistent pain in the proximal first and second metacarpals which is not responding to treatment, particularly in the dominant arm of throwing athletes. It is also important to consider the underlying intrinsic and extrinsic risk factors when treating any stress fracture.

## References

- Afifi, N. and Lu, J. (2011) A rare isolated trapezoid fracture. *Western Journal of Emergency Medicine* **12**, 523-524.
- Anderson, M.W. (2006) Imaging of upper extremity stress fractures in the athlete. *Clinics in Sport Medicine* **25**, 489-504.
- Ekstrand, J. and Torstveit, M.K. (2012) Stress fractures in elite male football players. *Scandinavian Journal of Medicine and Science in Sports* **22(3)**, 341-346.
- Gruson, K., Kaplan, K. and Paksima, N. (2008) Isolated trapezoid fractures - a case report with compilation of the literature. *Hand* **3**, 372-374.
- Kain, N. and Heras-Palou, C. (2012) Trapezoid fractures: report of 11 cases. *Journal of Hand Surgery* **37A**, 1159-1162.
- Kam, M.L.W., Sreedharan, S., Teoh, L.C. and Chew, W.Y.C. (2011) Severe isolated trapezoid fracture: a case report. *Hand Surgery* **16**, 185-187.
- Miyawaki, T., Kobayashi, M., Matsuura, S., Yanagawa, H., Imai, T. and Kurihara, K. (2000) Trapezoid bone fracture. *Annals of Plastic Surgery* **44**, 444-446.
- Nagumo, A., Toh, S., Tsubo, K., Ishibashi, Y. and Sasaki, T. (2002) An occult fracture of the trapezoid bone - a case report. *Journal of Bone and Joint Surgery* **84A**, 1025-1027.
- Otis, C.L., Drinkwater, B., Johnson, M., Loucks, A. and Wilmore, J. (1997) American College of Sports Medicine position stand. The Female Athlete Triad. *Medicine and Science in Sports and Exercise* **29(5)**, R1-R9.
- Pegrum, J., Crisp, T. and Padhiar, N. (2012) Diagnosis and management of bone stress injuries of the lower limb in athletes. *British Medical Journal* **24**, 344.
- Sadowski, R. and Montilla, R. (2008) Rare isolated trapezoid fracture: a case report. *Hand* **3**, 372-374.

## AUTHORS BIOGRAPHY

### Neil HERON

#### Employment

A family doctor Department of General Practice and Primary Care, Queen's University, Belfast, Northern Ireland

#### Degree

MD

#### Research interests

Physical activity promotion in the general population.

**E-mail:** neilheron@yahoo.co.uk

### ✉ Dr Neil Heron

Dept of General Practice, Queen's University, Dunluce Health Centre, Level 4, 1 Dunluce Avenue, Belfast, BT9 7HR, Northern Ireland

## Key points

- This is the first documented case report of a trapezoid stress fracture.
- Plain x-rays can be negative in stress fractures and therefore a high index of suspicion warrants further investigation with a CT scan and/or MRI of the relevant area.
- Non-displaced trapezoid fractures can be treated with immobilisation whereas displaced fractures will require surgical intervention.